



# ADVANCEMENTS IN NEUROSURGICAL PRACTICES: A CASE-BASED APPROACH

Dr. Nobuhiko Aoki



Index of Sciences Ltd.  
Kemp House, 160 City Road  
EC1V 2NX, London,  
U.K.



[www.indexofsciences.com](http://www.indexofsciences.com)




---

# ADVANCEMENTS IN NEUROSURGICAL PRACTICES: A CASE-BASED APPROACH

---

**Dr. Nobuhiko Aoki**



**About the author**

**Fighting Neurosurgeon Dr. Nobuhiko Aoki loves wine**

Copyright © 2024

All rights reserved. No part of this publication may be reproduced, distributed, or transmitted in any form or by any means, including photocopying, recording, or other electronic or mechanical methods, without the prior written permission of the AUTHOR, except in the case of brief quotations embodied in critical reviews and certain other non-commercial uses permitted by copyright law. For permission requests, write to the author, addressed “Attention: Permissions Coordinator,” at the address below.

Index of Sciences Ltd.  
Kemp House,  
160 City Road, London.  
[www.indexofsciences.com](http://www.indexofsciences.com)

Ordering Information:

Quantity sales. Special discounts are available on quantity purchases by corporations, associations, and others. For details, contact the publisher at the address above.

Printed in the United Kingdom  
ISBN:

## Preface

Clinical practice in neurosurgery is always very stringent. It is not uncommon for even a slight misjudgment to result in the occurrence of a permanent neurological deficit in a patient. The author believes, therefore, that neurosurgeons must be accountable for their patients on an emergency basis, being on call duty for twenty-four hours. The author has learned many clinical practices, including diagnostic examinations, surgical techniques, and postoperative management from the patients at the Neurosurgical Ward in Tokyo Metropolitan Fuchu Hospital since December 1971. The author devoted himself exclusively to duties in clinical practice during the initial ten years as a resident in this hospital. I suffered from duodenal ulcers repeatedly due to mental and physical stress, culminating in advanced pylorus stenosis, for which gastrectomy was performed in July 1981. Soon thereafter, considering that I had already been a neurosurgeon for ten years, I began to plan various experimental studies.

However, as a neurosurgeon constantly responsible for many in- and outpatients, I found it impossible to involve myself in basic research due to the lack of time and space. For this reason, the author planned to conduct clinical research ranking alongside the basic studies carried out at various universities. The subjects to be covered by clinical research should be those which contribute directly to daily clinical work. Based on this philosophy, the author has been engaged in clinical studies. This book contains articles by the author published in English in major neurosurgical journals between 1984 and 1990. All the articles were written about the patients I encountered at this hospital with whom I had experienced difficulties in diagnosis and treatment. I have never written these papers with the intention of negatively affecting the patients. Additionally, I admonished myself not to minimize my clinical duties by spending time on research work. All the papers were worked on little by little during intervals in my clinical practice on a desk with a width of one meter in the small doctors' room at this hospital. There were not a few occasions when I was almost frustrated, but I wrote the papers believing that they would be completed someday, provided that I kept on writing even if only a line a day. The author makes it a practice to read medical journals early in the morning at home. When I had certain questions regarding an article, I used to submit my questions to the column of "Letter to the Editor". Only the titles of such contributions are listed in this book. At present, the author is 45 years old, a time which can be said to be when my life as a neurosurgeon is entering the latter part. I think that this book will serve as the index for a turning point. In the future, with my accumulated reference files, I would like to help our junior neurosurgeons publish articles that can earn high assessments on an international basis.

Moreover, I hope to continue practicing optional neurosurgery that can serve as guidelines for our young colleagues.

Nobuhiko Aoki, MD, PhD, is a distinguished figure in the field of neurosurgery with a career spanning over five decades. Born on November 20, 1944, in Tokyo, Japan, Dr. Aoki embarked on his journey in medicine by graduating from the University of Tohoku, School of Medicine, Sendai-city, Japan, in 1970.

Throughout his illustrious career, Dr. Aoki has held numerous esteemed positions within the medical community. He commenced his professional tenure as a Staff Neurosurgeon in the Department of Neurosurgery at the Tokyo Metropolitan Fuchu Hospital in 1972. Over the years, he ascended through the ranks, serving as Chief Neurosurgeon and later as Vice Director at the same institution.

In 1991, Dr. Aoki assumed the role of Director of the Department of Neurosurgery at the Tokyo Metropolitan Okubo Hospital, where he further honed his expertise in the intricate field of neurosurgery. His outstanding contributions and leadership skills led to his appointment as Director of the Tokyo Metropolitan Tama Medical Center in 2010, a position he held until 2012, concurrently serving as the Honorary Director of the Tokyo Metropolitan Tama Medical Center.

Dr. Aoki's commitment to advancing the standards of neurosurgical practices propelled him to the position of Director of the Tama Northern Medical Center under the Tokyo Metropolitan Health Insurance Corporation in 2012. Currently, he holds the esteemed title of Director at Bethlehem Garden Hospital, a distinguished institution under the Jiseikai Social Welfare Corporation, a position he has held since 2014.

Throughout his career, Dr. Aoki has demonstrated an unwavering dedication to his craft, pioneering advancements in neurosurgical techniques and practices. His vast experience and expertise are showcased in his latest work, "Advancements in Neurosurgical Practices: A Case-Based Approach," where he shares invaluable insights and case studies garnered from his extensive professional journey.

Dr. Aoki's illustrious career and contributions to the field of neurosurgery have solidified his reputation as a trailblazer and a respected authority in the medical community. His tireless pursuit of excellence continues to inspire and shape the future of neurosurgical practices worldwide.

# Table of Contents:

## Chapter 1: Intracranial Vascular Anomalies and Fistulas

- 1.1 Overview of Cerebral Arteriovenous Malformations (Reference: 105, 110)
- 1.2 Case Studies on Intracranial Arteriovenous Fistula (Reference: 105)

## Chapter 2: Congenital and Acquired Spinal Disorders

- 2.1 Understanding Syringomyelia (Reference: 106)
- 2.2 Intraspinal Lipoma: Diagnosis and Management (Reference: 106)

## Chapter 3: Cerebrospinal Fluid Dynamics and Shunting Techniques

- 3.1 The Siphon Effect in CSF Shunting: A Myth? (Reference: 107)
- 3.2 Advances in Ventricular Drainage and Shunting Procedures (Reference: 111, 113, 120)

## Chapter 4: Management of Intraventricular Hemorrhages

- 4.1 Treatment Strategies for Intraventricular Hemorrhage (Reference: 108)
- 4.2 Percutaneous Techniques in Neurosurgery (References: 109, 116, 117)

## Chapter 5: Acute Subdural Hematomas: Challenges and Innovations

- 5.1 Percutaneous Subdural Tapping in Elderly Patients (Reference: 109)
- 5.2 Chronic Subdural Hematoma: New Therapeutic Approaches (References: 116, 117, 122, 128)

## Chapter 6: Cerebral Aneurysms and Vascular Dissections

- 6.1 Traumatic Aneurysms and Their Management (Reference: 112)
- 6.2 Case Report on Vertebral Artery Aneurysm (Reference: 118)

## Chapter 7: Pediatric Neurosurgery: Unique Challenges and Solutions

- 7.1 Infantile Acute Encephalopathy: A Diagnostic Challenge (Reference: 115)
- 7.2 Innovations in Pediatric Neurosurgery (References: 138, 139)

## Chapter 8: Neuroimaging in Neurosurgery: From Diagnosis to Postoperative Care

- 8.1 Role of MRI in Differentiating Extracerebral Fluid Collections (Reference: 123)
- 8.2 Serial Neuroimaging in Sotos Syndrome (Reference: 132)

## Chapter 9: Complications in Neurosurgery: Prevention and Management

- **9.1 Postoperative Complications: Case Studies and Management (Reference: 134)**
- **9.2 Cerebrovascular Bypass Surgery: Risks and Outcomes (Reference: 121)**

#### **Chapter 10: Neurosurgical Innovations and Technical Notes**

- **10.1 Ultrafine Microsurgical Techniques (Reference: 119)**
- **10.2 Needle Brain Necropsy: A Novel Technique (Reference: 137)**

# Chapter 1

## Intracranial Vascular Anomalies and Fistulas

### Overview of Cerebral Arteriovenous Malformations

Cerebral arteriovenous malformations (AVMs) are abnormal tangles of blood vessels in the brain. These tangles disrupt the normal flow of blood between arteries and veins. Unlike normal blood vessels, AVMs lack the tiny capillaries that usually connect arteries to veins. This can lead to high pressure and increased risk of bleeding in the brain.

AVMs are typically present at birth, but symptoms may not appear until later in life. Some people may experience symptoms such as seizures, headaches, or neurological deficits like weakness or numbness. However, some AVMs may remain asymptomatic and only be discovered incidentally during brain imaging for another condition.

Diagnosis of AVMs often involves imaging tests such as MRI, CT scans, or cerebral angiography, which provide detailed pictures of blood flow in the brain. Treatment options for AVMs include surgery to remove the malformation, embolization to block blood flow to the AVM, or radiosurgery to shrink the malformation.

However, the choice of treatment depends on factors such as the size and location of the AVM, as well as the individual's overall health. Additionally, some AVMs may be closely monitored without intervention if they pose a low risk of bleeding or symptoms.

Overall, cerebral arteriovenous malformations require careful evaluation and management to prevent complications such as hemorrhage and neurological deficits. Regular follow-up with healthcare providers is important for monitoring the condition and adjusting treatment as needed.

### Does the Presence of Intracranial Arteriovenous Malformations Result in Subarachnoid Hemorrhage?

In the realm of neurosurgery, the presence of intracranial arteriovenous malformations (AVMs) has long been associated with subarachnoid hemorrhage (SAH), a serious condition characterized by bleeding in the space surrounding the brain. This association, alongside intracranial aneurysms, has been highlighted in numerous medical texts and literature as a hallmark of diseases leading to

SAH. However, recent advancements in medical imaging, particularly computed tomography (CT), have raised questions regarding this classic concept.

Contrary to earlier beliefs, CT scans of patients with AVM rupture often reveal bleeding within the brain tissue or ventricles rather than in the subarachnoid space. This discrepancy has led to doubts regarding whether AVMs are indeed the primary cause of SAH. Early observations by Leblanc et al. noted the infrequency of detecting subarachnoid blood in patients with ruptured AVMs, casting further doubt on the traditional understanding. Recent studies have similarly challenged the notion that AVMs are a common source of primary SAH.

Despite these findings, there remains a lack of consensus among neurosurgeons regarding the role of AVMs in causing SAH. To address this uncertainty, this chapter aims to delve into the characteristics of hemorrhage resulting from AVM rupture. Through a comprehensive review of AVM patients with intracranial hemorrhage, confirmed by CT scans in the acute stage, we will examine both the author Nobuhiko Aoki's findings and relevant reports from the literature. By shedding light on the nuanced features of AVM-related hemorrhage, this exploration seeks to contribute to a deeper understanding of this complex pathological condition.

## **Materials and Methods**

This study looked at patients from the author's hospital and existing medical literature who were diagnosed with intracranial arteriovenous malformations (AVMs) through a brain blood vessel imaging test called cerebral angiography. These patients also had bleeding inside their skull, confirmed by a type of brain imaging called CT scan, during the early stages of their condition.

Patients with certain types of AVMs or with an associated brain artery abnormality called an intracranial aneurysm were not included in the study.

The study included 50 patients who were treated at the Department of Neurosurgery, Tokyo Metropolitan Fuehu Hospital, between 1978 and 1989, when CT scans became available. Among these patients, there were 30 males and 20 females, with ages ranging from 5 to 78 years, and an average age of 30 years (see Table 1 for details).

**Table 1: Age Distribution of 50 Patients with Ruptured Arteriovenous Malformations**

Age (years)	Number of patients (%)
0-10	8 (16)
11-20	11 (22)
21-30	14 (28)
31-40	3 ( 6)
41-50	10 (20)
51-60	2 ( 4)
61-70	1 ( 2)
71-80	1 ( 2)

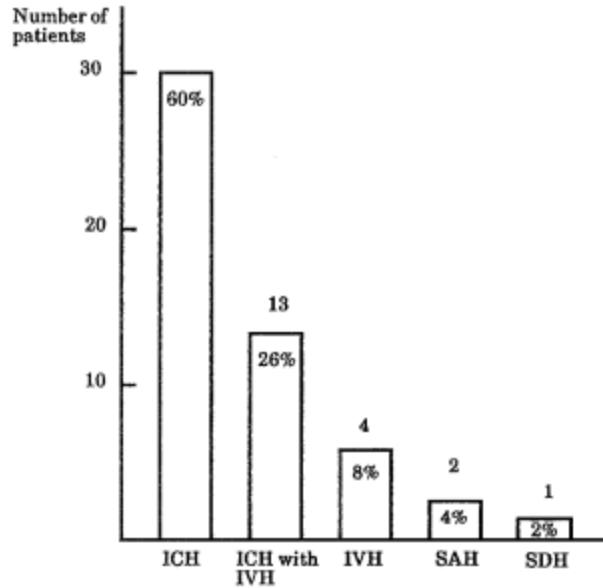
The bleeding in these patients was categorized into different types: bleeding within the brain (intracerebral hemorrhage or ICH), bleeding into the brain's fluid-filled spaces (intraventricular hemorrhage or IVH), bleeding around the brain (subarachnoid hemorrhage or SAH), and bleeding between the brain and its outer covering (subdural hematoma).

## Results

In the study, Table 2 displays where the arteriovenous malformations (AVMs) were located in the patients seen by the author. Figure 1 illustrates the areas where bleeding occurred. Among the patients, 30 experienced bleeding within the brain (called intracerebral hemorrhage or ICH), which accounted for 60% of cases. Thirteen patients had a combination of ICH and bleeding into the brain's fluid-filled spaces (intraventricular hemorrhage or IVH), making up 26% of cases. IVH alone occurred in 4 patients (8%), while 2 patients (4%) had bleeding around the brain (subarachnoid hemorrhage or SAH). One patient (2%) had bleeding between the brain and its outer covering (subdural hematoma). Interestingly, one patient each with SAH had the AVM located in the left posterior temporal region and the cerebellar valleculla. Their CT scans showed isolated SAH in the left temporal region and in the basal cistern, respectively.

**Table 2: Location of Ruptured Arteriovenous Malformations in 50 Patients**

Site	Number of patients (%)
Cerebral hemisphere	35 (70)
Corpus callosum/Ventricle	3 ( 6)
Basal ganglia/Thalamus	8 (16)
Cerebellum/Brain stem	4 ( 8)



*Figure 1: Location of Bleeding from Ruptured Arteriovenous Malformations in 50 Patients, Confirmed by CT Scan. This figure shows where bleeding occurred due to ruptured arteriovenous malformations in the brains of 50 patients. The abbreviations stand for different types of bleeding: ICH for intracerebral hemorrhage, IVH for intraventricular hemorrhage, SAH for subarachnoid hemorrhage, and SDH for subdural hematoma.*

Table 3 presents findings from CT scans of patients described in the medical literature. These patients were not from the author's study but were included for comparison. The majority of them had either ICH or IVH. Isolated SAH was uncommon, occurring in only three out of 70 patients in one study. Another study reported that two out of 21 patients had ICH along with SAH, where SAH was described as a result of the bleeding within the brain. Other studies conducted in the CT era similarly found that only a small proportion of patients developed SAH, with most experiencing ICH or IVH exclusively.

*Table 3: Location of Bleeding in Patients with Ruptured Arteriovenous Malformations, as Reported in Published Studies Using Computed Tomography*

Authors (year)	Total number of patients with intracranial haemorrhage	Number of patients by site of haemorrhage				
		ICH	IVH	ICH with IVH	ICH with SAH	SAH
Takahashi <i>et al.</i> <sup>14</sup> (1982)	10	7		3		
Mitsugi <i>et al.</i> <sup>13</sup> (1985)	21	7		12	2*	
Miyasaka <i>et al.</i> <sup>15</sup> (1989)	70	25		42**		3
Fu <i>et al.</i> <sup>16</sup> (1989)	7	3		4		

## Discussion

Despite the advancements in CT scanning, which allow for detailed examination of pathological features, some older ideas from before the era of CT scans haven't been re-evaluated critically. Subarachnoid hemorrhage (SAH) is one such condition. In some cases, doctors might diagnose SAH based on finding bloody fluid in the cerebrospinal fluid through a lumbar puncture, even if CT scans show bleeding primarily within the brain tissue or the ventricular system. This approach isn't accurate because SAH should only be diagnosed when blood is found directly in the subarachnoid space, not when it's drained there secondarily from bleeding within the brain or ventricles.

Moyamoya disease, once thought to be a common cause of SAH in Japan before CT scans, has since been reassessed. It's now understood that it typically leads to bleeding within the brain tissue or ventricles rather than primary SAH. Similarly, ruptured arteriovenous malformations (AVMs) have often been thought to cause primary SAH, but our study suggests that this is rare. This observation has been noted before but isn't universally accepted among neurosurgeons.

When an AVM is located in the brain stem or has an abnormal position outside the usual brain covering (pial), primary SAH might be more likely. However, most AVMs are found within the brain tissue, and their rupture commonly results in intracerebral hemorrhage (ICH) or bleeding into the ventricles.

AVMs are often associated with intracranial aneurysms, which develop due to changes in blood flow. When both an AVM and an aneurysm are present, it's crucial to determine which one caused the bleeding to decide the best treatment approach. Some experts suggest treating the aneurysm first, especially when the source of bleeding isn't clear. However, if the source of bleeding is identified, it's reasonable to address it first, especially if emergency surgery is needed or if the AVM is in a critical area of the brain.

Our study, including data from the author's hospital and other reported cases, found that only a small percentage of patients with ruptured AVMs developed primary SAH. Similarly, in a larger study of patients with SAH in the CT era, only a tiny fraction were caused by AVM rupture. Therefore, while AVMs can lead to bleeding in the brain, they shouldn't be considered a major cause of primary SAH. Instead, they're more commonly associated with ICH or bleeding into the ventricles.

## **Conclusion**

In conclusion, our examination of intracranial arteriovenous malformations (AVMs) and their association with subarachnoid hemorrhage (SAH) sheds light on the complexities of diagnosing and treating these conditions. Despite the availability of advanced imaging techniques like CT scans, certain traditional concepts regarding SAH diagnosis have persisted without critical re-evaluation. Our study, led by author Nobuhiko Aoki, contributes to this ongoing discussion by analyzing data from our hospital and existing literature.

We found that while AVMs have long been considered a potential cause of primary SAH, our findings suggest that this occurrence is rare. Instead, most cases of AVM rupture result in intracerebral hemorrhage (ICH) or bleeding into the brain's ventricles. This challenges the traditional understanding and highlights the importance of re-evaluating diagnostic criteria for SAH.

Furthermore, our study underscores the association between AVMs and intracranial aneurysms, emphasizing the need to accurately identify the source of bleeding to guide treatment decisions. While some experts advocate for treating the aneurysm first in cases of uncertainty, our findings suggest that addressing the identified source of bleeding may be more appropriate, especially in critical situations.

Overall, our study contributes to a better understanding of the pathology and clinical implications of AVM-related hemorrhage. By questioning traditional concepts and providing evidence-based insights, we aim to improve patient care and inform decision-making in the management of intracranial AVMs and associated bleeding complications.

# Chapter 2

## Congenital and Acquired Spinal Disorders

### Understanding Syringomyelia

Syringomyelia is a condition that affects the spinal cord. Normally, the spinal cord is a long, thin bundle of nerves that runs down the back and carries messages between the brain and the rest of the body. In syringomyelia, a fluid-filled cyst, called a syrinx, forms within the spinal cord. This cyst can grow over time, putting pressure on the spinal cord and causing damage to the nerves. This can lead to a range of symptoms, including pain, weakness, numbness, and problems with coordination. The exact cause of syringomyelia isn't always clear, but it's often associated with conditions like Chiari malformation, spinal cord injury, or tumors. Treatment typically focuses on managing symptoms and may include medications, physical therapy, and in some cases, surgery to drain the cyst or relieve pressure on the spinal cord. Early diagnosis and treatment are important for managing the condition and preventing further damage to the spinal cord.

### Intraspinal Lipoma: Diagnosis and Management

Intraspinal lipoma is a type of fatty tumor that grows within the spinal canal, which is the space that houses the spinal cord. This condition is usually present from birth and involves an abnormal development of fat tissue within the spine. Intraspinal lipomas can vary in size and location along the spine, and they can cause symptoms by compressing the spinal cord or nerve roots. Diagnosis of intraspinal lipoma typically involves imaging tests such as MRI or CT scans, which can show the location and extent of the tumor. Management of intraspinal lipoma depends on the severity of symptoms and the risk of complications. In some cases, especially if the tumor is small and not causing symptoms, observation and regular monitoring may be recommended. However, if the lipoma is causing symptoms like pain, weakness, or problems with bladder or bowel function, surgical removal of the tumor may be necessary to relieve pressure on the spinal cord and nerves. The goal of treatment is to alleviate symptoms, prevent further neurological damage, and improve quality of life for affected individuals.

### Secondary Syringomyelia Associated with Congenital Intraspinal Lipoma

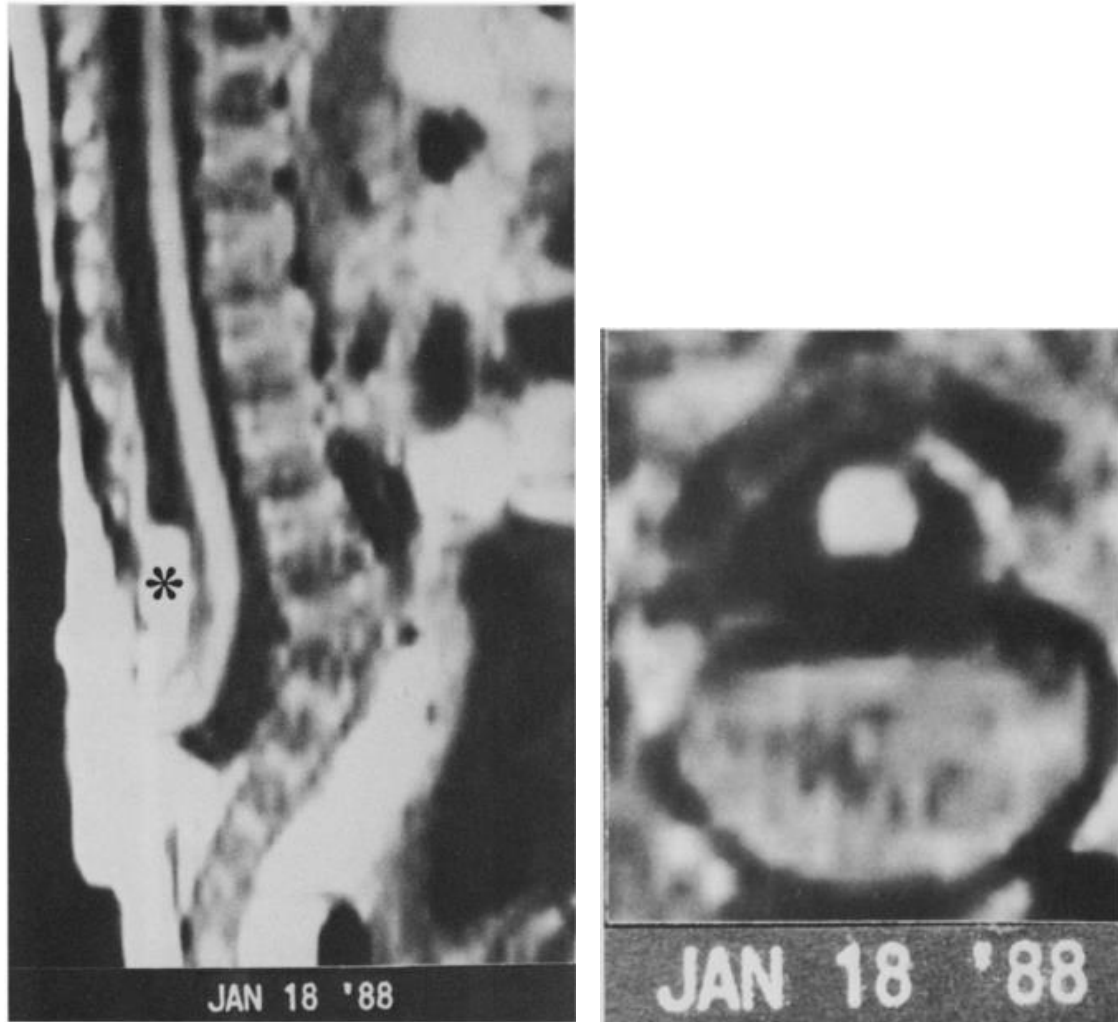
With the introduction of magnetic resonance imaging (MRI), our understanding of the spinal cord's pathology in conditions like congenital intraspinal lipoma, lumbosacral lipoma with spina bifida,

and lipomyelomeningocele has greatly improved. These imaging techniques have allowed for precise visualization of the spinal cord's features in affected patients, shedding light on previously obscure aspects of these conditions. However, despite the advancements in imaging technology, only a handful of studies have delved into the preoperative evaluation of these conditions using serial MRI scans.

Nobuhiko Aoki, the author of this chapter, has conducted extensive research on this topic, particularly focusing on patients with congenital intraspinal lipoma. In their practice, they have encountered seven patients with this condition, two of whom underwent preoperative serial MRI scans. Notably, in both infants, rapid growth of the intraspinal lipoma was observed, accompanied by the formation of a syrinx. These observations highlight a crucial aspect of the pathological process of this condition, providing valuable insights into its progression and potential complications. While one of these cases has been previously reported regarding the rapid growth of the lipoma, this chapter aims to provide a detailed account of another patient's experience, further enriching our understanding of this complex entity.

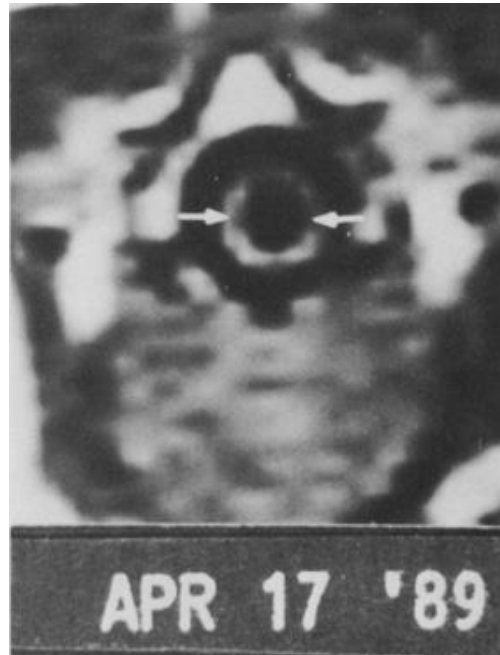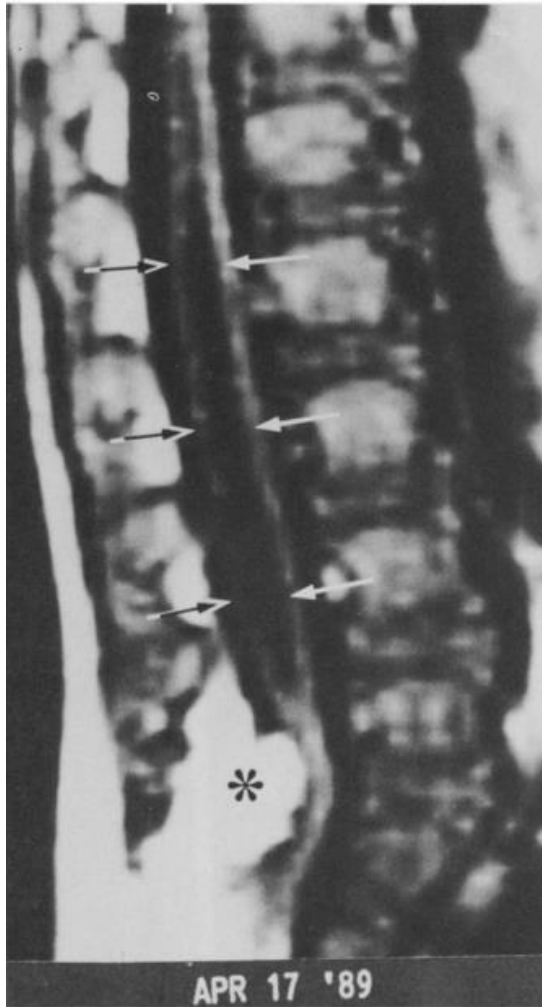
## **Case Report**

A baby boy was born on January 9, 1988, following a normal pregnancy and delivery. Soon after birth, doctors noticed a fatty lump under the skin in his lower back area, which looked discolored. However, when they checked his nervous system, everything seemed normal. When the baby was just 9 days old, an MRI scan showed that the end of his spinal cord was lower than usual and that he had a fatty lump inside his spine along with a condition called spina bifida, where the spine doesn't close completely (Figure 1).

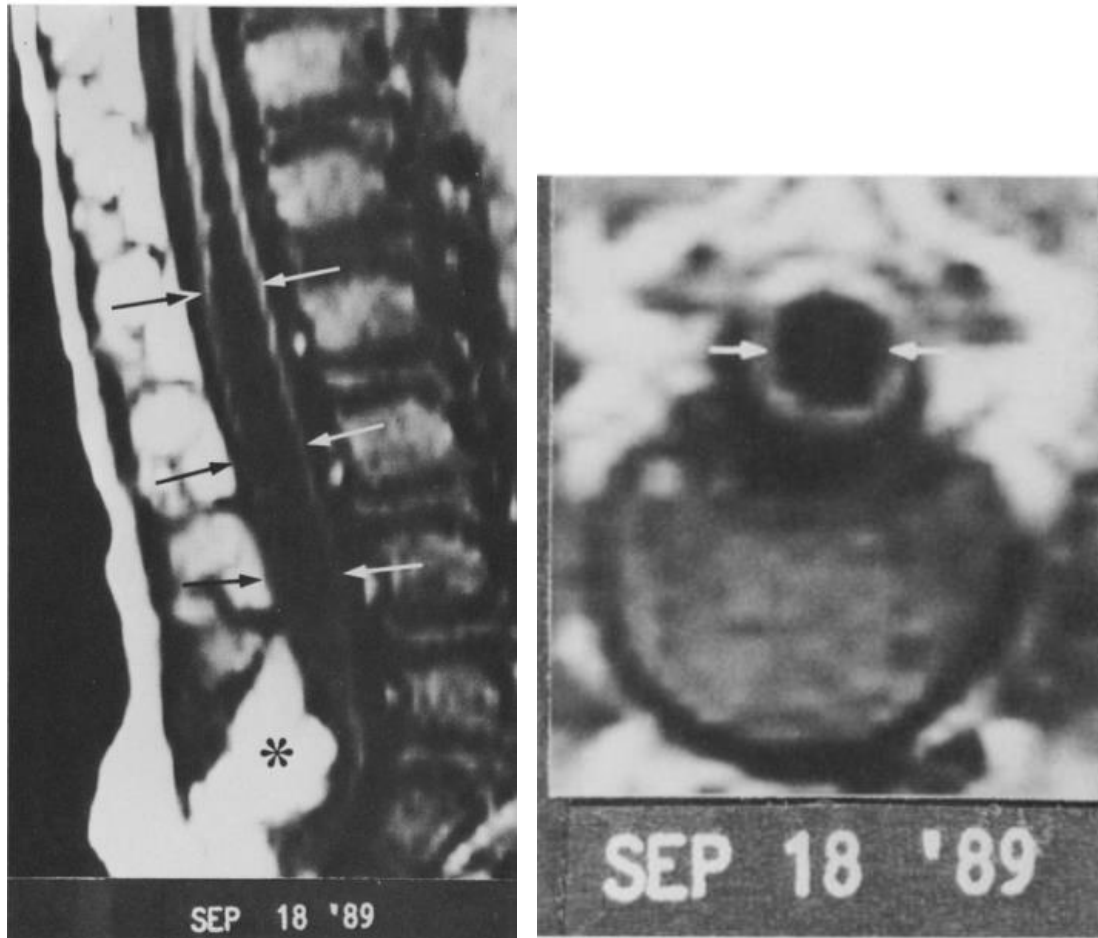


*Figure 1 shows an MRI scan taken when the baby was 9 days old. It's a type of MRI called T1-weighted, which helps doctors see certain details. The image on the left is a side view (sagittal), and the one on the right is a front view (coronal). In the scan, you can see that the end of the spinal cord is lower than usual (indicated by "lowered conus"), and there's a fatty lump inside the spine in the lower back area (marked by an asterisk), which is called an intraspinal lipoma.*

For a while, the family decided to keep an eye on things without surgery. But by the time the baby was 1 year and 3 months old, another MRI showed that the fatty lump had grown a lot, and there was now a large pocket of fluid called a syrinx just above it (Figure 2). Despite these changes, the baby didn't show any problems with his nervous system. Surgery was planned for September 1989, when the baby was 1 year and 8 months old. Another MRI just before the surgery showed that the syrinx had gotten even bigger, but the size of the fatty lump hadn't changed much (Figure 3).

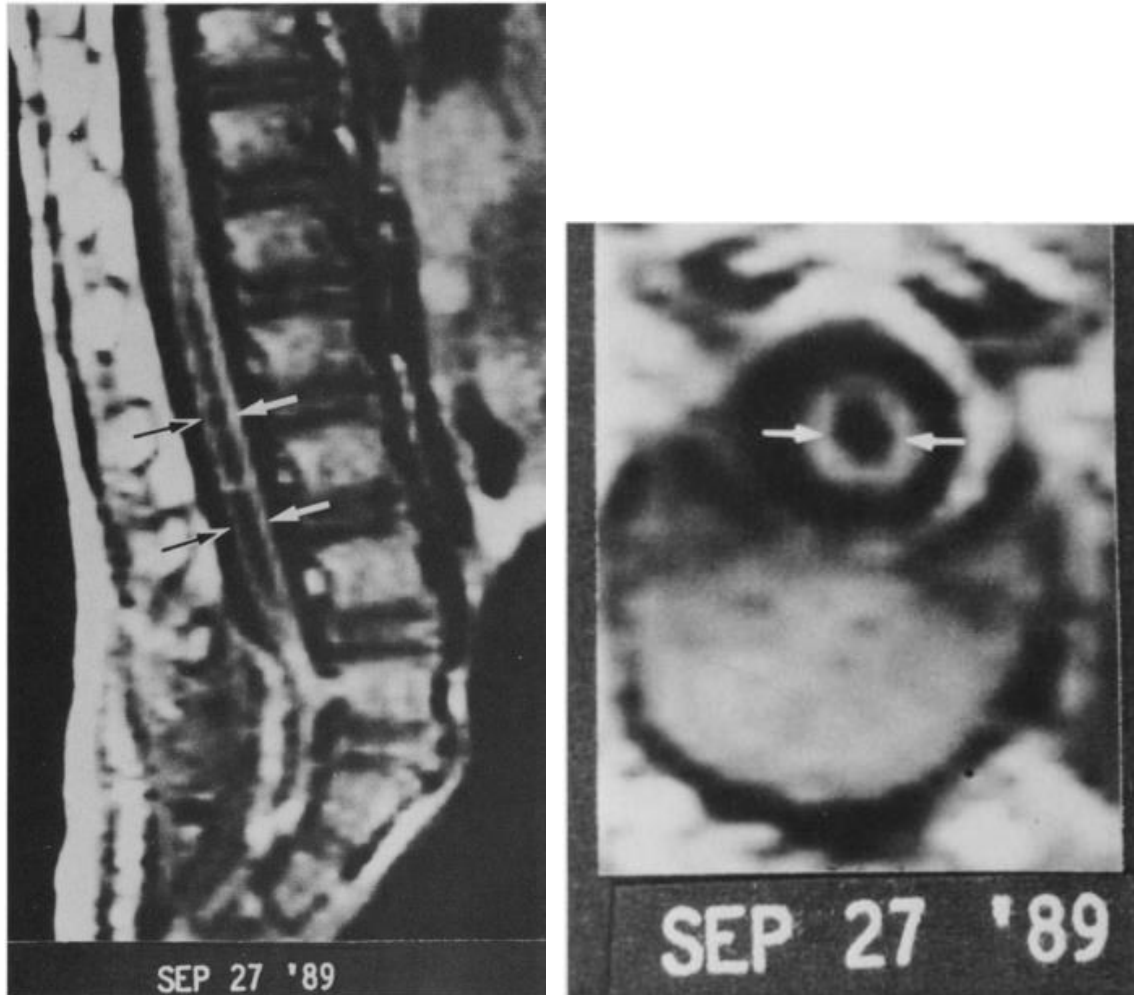


*Figure 2 shows another MRI scan, taken when the baby was 1 year and 3 months old. Just like in the previous scan, it's a T1-weighted MRI. The image on the left is a side view (sagittal), and the one on the right is a front view (coronal). In this scan, you can see that the fatty lump inside the spine (marked by an asterisk) has grown a lot, and there's now a big pocket of fluid called syringomyelia (shown by arrows).*



*Figure 3 displays another MRI scan, taken when the baby was 1 year and 8 months old. Again, it's a T1-weighted MRI, with a side view (sagittal) on the left and a front view (coronal) on the right. In this scan, you can see that the pocket of fluid called syringomyelia has gotten even bigger (indicated by arrows). However, the size of the fatty lump inside the spine (marked by an asterisk) has stayed the same.*

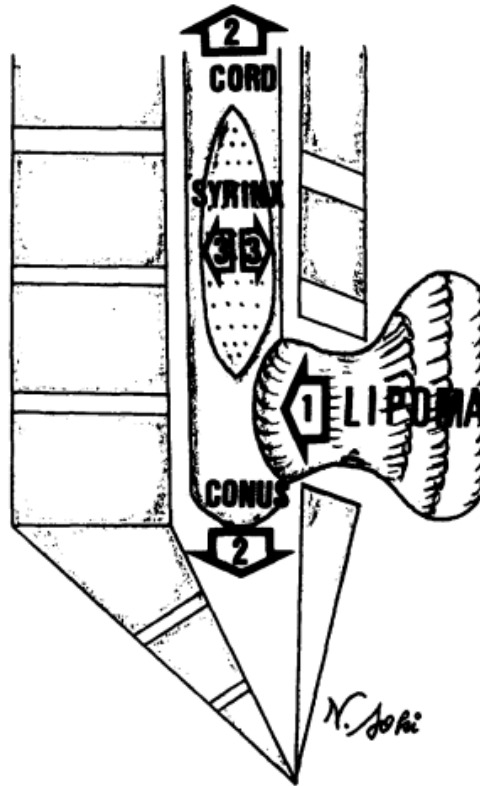
During the surgery on September 19, most of the fatty lump was removed, but a small part was left because it was connected to the end of the spinal cord. Doctors also cut a small piece of tissue called the filum terminale, which was part of the fatty lump. They didn't do any procedures to drain the fluid pocket. After surgery, the baby had some temporary issues like difficulty walking steadily and decreased reflexes in his anal muscles. But nine days later, another MRI showed that the syrinx had shrunk (Figure 4). Two months later, when the baby was checked again, only the reflexes in his anal muscles were still a bit weaker.



*Figure 4 shows an MRI scan taken 9 days after the fatty lump inside the spine was removed through surgery. It's still a T1-weighted MRI, with a side view (sagittal) on the left and a front view (coronal) on the right. In this scan, you can see that the pocket of fluid called syringomyelia has shrunk a lot (indicated by arrows).*

## **Discussion**

Congenital intraspinal lipoma often comes with various issues, like syringomyelia, a condition where fluid-filled pockets form in the spinal cord. However, it's not clear whether this syringomyelia happens because of the lipoma itself or if it's something that develops separately. While it's common for people with tumors inside the spinal cord to have these fluid pockets, it's rare with tumors outside the spinal cord. In my experience, though, two out of seven patients with intraspinal lipoma had syringomyelia, suggesting it might be more common than we thought. We think that the pressure from the tumor might enlarge spaces around the spinal cord, allowing fluid to enter where it shouldn't. In this case, the fluid pocket got smaller after the tumor was removed, supporting this idea.



*Figure 5 illustrates the potential reasons for spinal problems in people with intraspinal lipoma. The first reason is pressure from the lipoma pressing on the spinal cord (compression from lipoma). The second reason is when the lipoma tugs on the spinal cord, affecting its function (tethering). The third reason is the formation of a syrinx, which is a pocket of fluid in the spinal cord. These factors can all contribute to spinal dysfunction in individuals with intraspinal lipoma.*

Luckily, this patient didn't show any nerve problems from the syringomyelia, but he could have been at risk. It's known that most people with congenital intraspinal lipoma start having serious problems around age 4. This might happen because the tumor presses on the spinal cord or tugs on it, causing issues with how the nerves work. Even though I've only seen this in two patients, having syringomyelia might add to the risk of nerve problems later on. Getting rid of the lipoma could help the syringomyelia get better without needing separate surgery for it.

## **Conclusion**

In conclusion, the findings discussed in this study shed light on the complex relationship between congenital intraspinal lipoma and associated conditions like syringomyelia. Through the experiences documented by the author, Nobuhiko Aoki, it becomes evident that syringomyelia may occur more frequently in patients with intraspinal lipoma than previously recognized. The mechanism behind syrinx formation in these cases appears to involve the compression of the spinal cord, leading to abnormal fluid dynamics and the enlargement of spaces around the nerves. However, the timely intervention, such as surgical removal of the lipoma, can lead to the resolution

of syringomyelia and potentially prevent the development of neurological deficits later in life. These insights underscore the importance of early detection and management of congenital intraspinal lipoma to minimize the risk of complications and improve long-term outcomes for affected individuals. Further research in this area may help refine our understanding of these conditions and enhance treatment strategies to better serve patients in the future.

# Chapter 3

## Cerebrospinal Fluid Dynamics and Shunting Techniques

### **The Siphon Effect in CSF Shunting: A Myth?**

The Siphon Effect in CSF shunting is a concept that some doctors and researchers debate. This theory suggests that when a person with a shunt system moves from lying down to standing up, it creates a suction-like effect that can drain too much cerebrospinal fluid (CSF) from the brain. This rapid drainage might lead to complications such as headaches or over-draining of CSF. However, whether this effect truly happens or not is still uncertain, and more research is needed to understand its role in shunt management and patient care.

### **Is the Siphon Effect of Cerebrospinal Fluid Shunting Evident in vivo? Case Report Challenging the Existence of this Phenomenon**

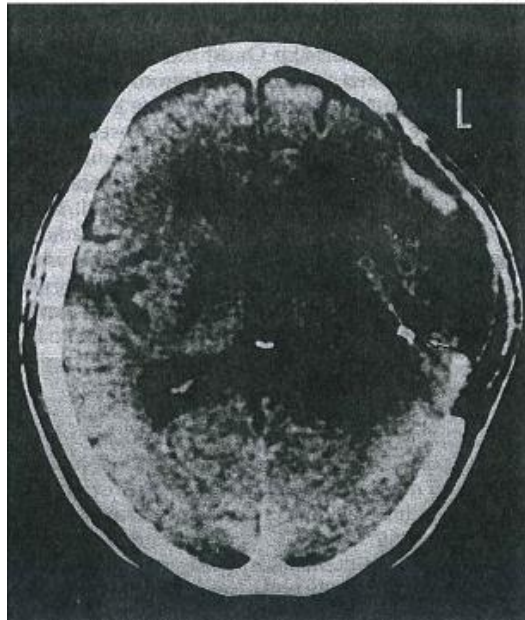
In the realm of cerebrospinal fluid (CSF) shunting, a curious phenomenon emerges when patients assume an upright position: notable negative intracranial pressures are often recorded. Traditionally, this occurrence has been attributed to the siphon effect within the CSF shunting systems. However, a closer examination reveals complexities, particularly when considering individuals beyond infancy. Unlike infants, whose cranial contents are more exposed to atmospheric pressure due to less rigid skull and vertebral structures, adults possess a more rigidly enclosed CSF environment, courtesy of robust skull and vertebrae, alongside associated muscles and ligaments.

Consequently, questions arise regarding the validity of attributing this phenomenon solely to atmospheric pressure-induced siphoning in vivo. Nobuhiko Aoki, a prominent figure in this field, presents an intriguing case study involving serial computed tomography (CT) scans conducted before and after cranioplasty in an adult patient treated with lumboperitoneal shunting. This unique observation offers valuable insights into the reassessment of the purported siphon effect of CSF shunting within living organisms.

### **Case Report: Recovery Following Severe Brain Hemorrhage**

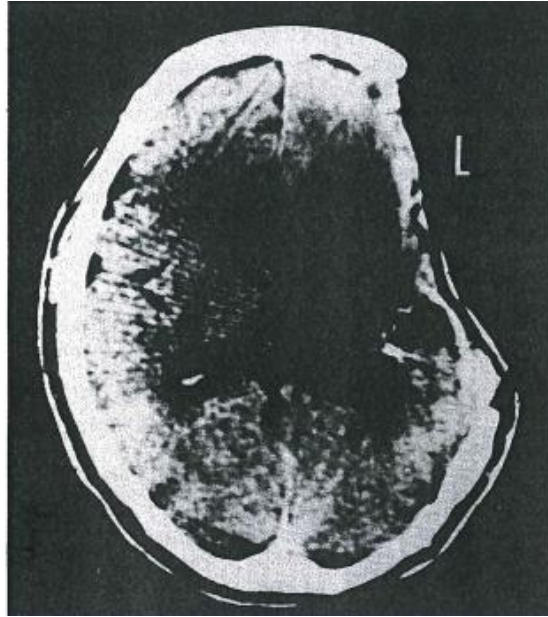A 52-year-old man arrived at the Department of Neurosurgery, Tokyo Metropolitan Fuchu Hospital, in January 1987 in a comatose state. Scans revealed a massive brain hemorrhage due to

a condition called moyamoya disease, which had ruptured on the left side, causing bleeding from the putamen to the temporal lobe. He underwent urgent surgery to remove the blood clot, which helped him regain consciousness, but he remained paralyzed on his right side and had difficulty speaking.

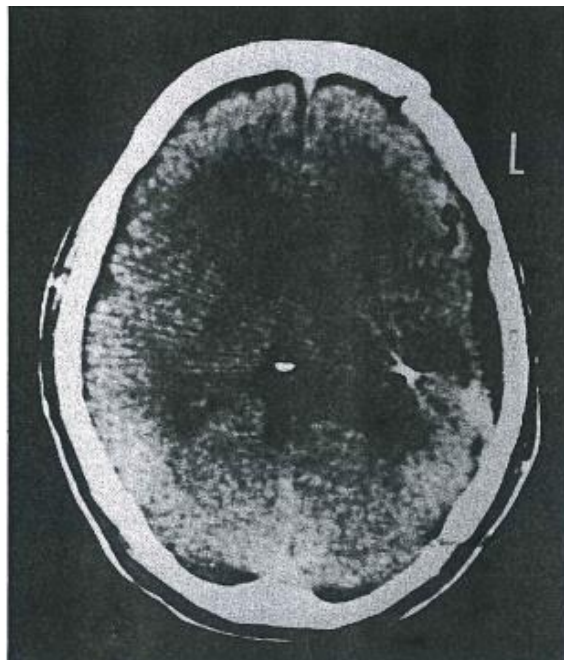

*Figure 1 shows a CT scan taken after a decompressive craniectomy. It reveals swelling at the site where part of the skull was removed, and it also shows that the ventricles, which are fluid-filled spaces in the brain, are larger than usual, especially on the left side. An arrow points to a clip that was used to seal off a ruptured artery.*

A follow-up scan in late January showed that the left side of his brain had expanded, and there was a bulge where part of his skull had been removed during surgery. To relieve pressure on his brain and improve his condition, the doctors performed a procedure called lumboperitoneal (LP) shunting in mid-February. After this surgery, another scan showed that parts of his brain had shifted to the right side, and his cognitive abilities slightly improved. Later, in March, he underwent a surgery to repair his skull using his own bone tissue. By the end of March, scans showed that his brain structures had somewhat returned to their normal positions, indicating a moderate improvement in his condition. (See Figures 1, 2, and 3 for visual representations of his brain scans at different stages of treatment.)



*Figure 2 displays a CT scan taken after lumboperitoneal shunting. It shows that the area of the skull where a piece was removed during surgery now appears concave or curved inward. Additionally, it indicates that structures inside the brain have moved towards the right side.*

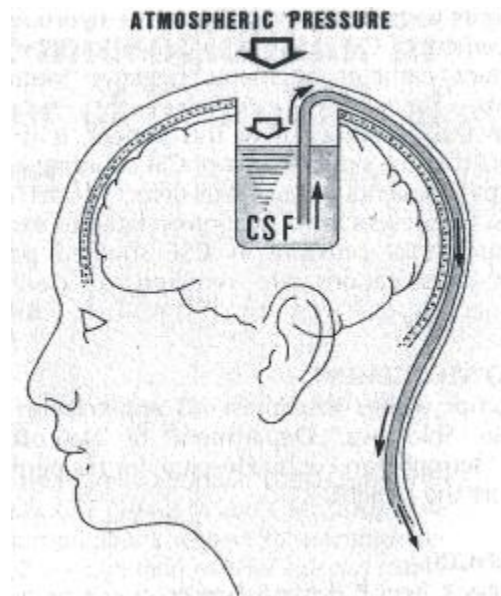


*Figure 3 shows a CT scan taken after cranioplasty, a surgical procedure where the patient's own skull bone is used to repair a defect in the skull. The scan reveals that the structures inside the brain have returned to their normal positions, indicating successful restoration.*

## Discussion

Patients who undergo CSF shunting can face various complications such as headaches, vomiting, and bleeding around the brain due to very low pressure inside the skull. Recently, there have been reports of even minor head injuries causing serious bleeding in these patients. These issues are often blamed on something called the siphon effect, where the shunt system creates a suction-like force due to differences in pressure. To counteract this, a device called the antisiphon valve has been used for many years. However, there's debate about whether this siphon effect really happens in patients whose CSF isn't much exposed to outside pressure.

One patient in this study had surgery to remove part of their skull and then had a shunt placed. They experienced pressure changes in their brain that improved after the skull was repaired. This suggests that without a skull defect, the brain might not be affected by the siphon effect as much. Instead, other factors like the movement of fluid within the brain or changes in blood flow might be responsible for pressure changes. More research is needed to fully understand and prevent complications in CSF shunted patients. (See Figure 4 for an illustration of the siphon effect.)



*Figure 4 is a simple drawing that explains the siphon effect in cerebrospinal shunting. It shows how the shunt system works in a patient who has a defect in their skull.*

## Advances in Ventricular Drainage and Shunting Procedures

Advances in Ventricular Drainage and Shunting Procedures have significantly improved the treatment of conditions like hydrocephalus, where excess fluid builds up in the brain's ventricles. In recent years, new techniques and technologies have made these procedures safer and more effective. One key advancement is the development of minimally invasive techniques, which involve smaller incisions and less disruption to surrounding tissues. This not only reduces the risk of complications but also leads to quicker recovery times for patients.

Additionally, innovations in shunt materials and designs have improved the durability and reliability of these devices, reducing the need for repeated surgeries. Another important development is the use of advanced imaging techniques, such as MRI and CT scans, to better plan and monitor these procedures, ensuring precise placement of drainage devices and optimal outcomes for patients. Overall, these advances represent significant strides in the field of neurosurgery, offering hope to patients with hydrocephalus and other conditions requiring ventricular drainage and shunting.

## **A Rapid Bedside Technique for Percutaneous Ventricular Drainage in Patients with Severe Subarachnoid Hemorrhage: A Technical Note**


In the treatment of severe subarachnoid hemorrhage caused by ruptured cerebral aneurysms, immediate management of intracranial pressure alongside aggressive postoperative care can significantly improve the chances of meaningful recovery for patients. While percutaneous ventricular drainage has been a longstanding practice in neurosurgery, its application specifically for acute subarachnoid hemorrhage has been seldom discussed in existing literature. Thus, it is timely to introduce a simple yet refined technique developed by Nobuhiko Aoki, aimed at facilitating percutaneous ventricular drainage at the patient's bedside. This chapter seeks to shed light on the importance and feasibility of this technique in improving outcomes for patients experiencing severe subarachnoid hemorrhage, providing valuable insights for neurosurgical practice.

### **Device and Technique Description**

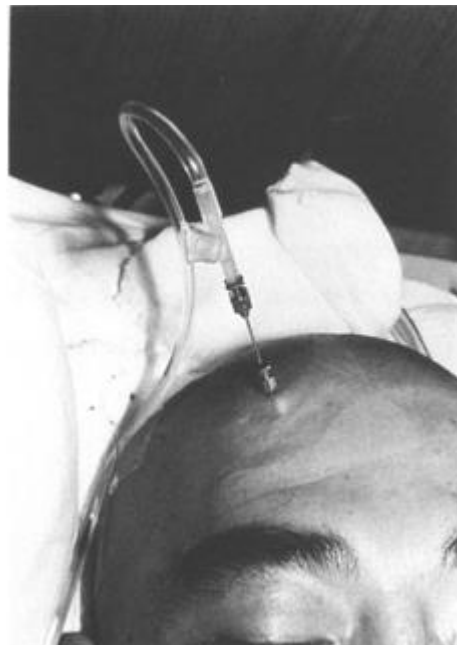The author has developed a special needle for a procedure called percutaneous ventricular drainage, mainly used in adult patients with chronic subdural hematoma. This needle is part of a kit that also includes a blunt-tipped needle designed to enter the ventricle of the brain. First, the area of the scalp where the needle will be inserted is shaved, and then a small amount of local anesthetic is injected to numb the area. The puncture site is marked on the right side of the head, usually about 1 cm in front of the coronal suture and 3 cm away from the midline. The percutaneous tapping is directed towards a specific part of the brain's ventricle.

Once the needle punctures the protective layer around the brain (called the dura mater), the inner part of the needle is removed, and the ventricular needle is inserted through the outer part of the

first needle. After confirming a steady flow of cerebrospinal fluid, the needle is advanced a bit further, and then it's slightly bent to avoid going too deep. Finally, a drainage system is connected to the ventricular needle. For patients who need long-term drainage or those who are restless, the needle may be replaced with a thinner tube called a catheter.



*Figure 5 shows a ventricular tapping assembly. It consists of an outer needle (labeled O), an inner needle (labeled I), and a ventricular needle (labeled V).*



*Figure 6 is a photo taken during external ventricular drainage.*

## **Comment**

In Japan, there's a growing trend to treat severe subarachnoid hemorrhage promptly. To prevent worsening of neurological conditions early on, doctors often use immediate ventricular drainage. For patients who are in poor condition before surgery, it's better to use techniques that are less invasive and simpler. One such technique is percutaneous ventricular drainage, which has been used in various hospitals.

The method described here is considered the most straightforward. So far, more than ten patients with severe subarachnoid hemorrhage have been successfully treated using this technique without any issues. What's unique about this method is that it makes it easier to replace the needle or tube used for drainage if it gets blocked by blood clots inside the brain. Because it's simple and less invasive, this technique is valuable for neurosurgeons who need to treat emergency cases of severe subarachnoid hemorrhage.

## **Subdural-Peritoneal Shunt: One-Piece Design with a Large Flushing Device**

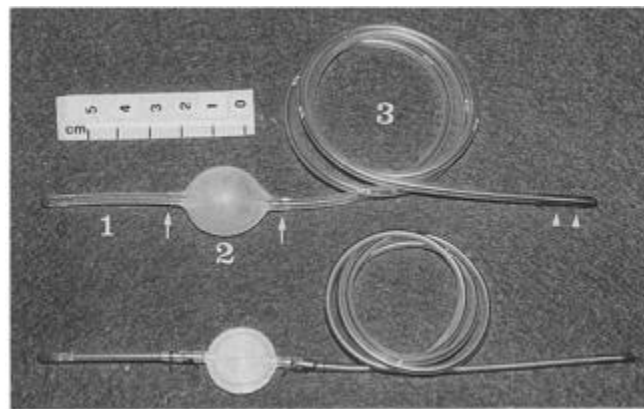
Infantile chronic subdural hematoma remains a complex issue in neurosurgery, posing challenges for both pediatric neurosurgeons and neurologists. Despite collaborative efforts, treatment outcomes for patients with this condition often fall short of expectations. However, there's a recent shift in focus towards managing intracranial pressure without resorting to invasive craniotomy procedures. In this context, the use of subdural-peritoneal shunting has gained considerable attention. Unlike ventriculoperitoneal shunting, which is commonly used for hydrocephalus, subdural-peritoneal shunting in infantile chronic subdural hematoma faces unique challenges.

The presence of hematoma contents, including blood and high-protein fluid, can lead to complications such as blockages in the shunt system. To address this issue, Nobuhiko Aoki has previously developed a subdural-peritoneal shunt with a large-caliber catheter and a low-pressure slit valve. In this chapter, a newly refined version of this shunt system is introduced. This updated design incorporates a large flushing device with a one-way valve, all integrated into a single unit. With this improved shunt system, we anticipate achieving excellent treatment outcomes. This chapter aims to provide a detailed account of the features and benefits of this integrated shunt system, highlighting its potential to enhance patient care in infantile chronic subdural hematoma cases.

## **Materials and Methods**

The subdural-peritoneal shunt system described here consists of three main parts. The first part is a large tube that goes into the space where the subdural hematoma is located. This tube is about

2.5 mm wide on the inside, 3.5 mm wide on the outside, and 4.5 cm long. The second part is a flushing device that has a one-way valve. It's shaped like a small box, about 25 mm long, 20 mm wide, and 10 mm tall. This device is connected directly to both the first tube and a third tube, without needing any extra connectors. The third part, called the distal catheter, is the same size as the first tube and is about 70 cm long. It has a special valve at the end that only opens when the pressure is very low, between 0 and 20 mm H<sub>2</sub>O. This shunt system is made by Fuji Systems Corporation in Tokyo, Japan.

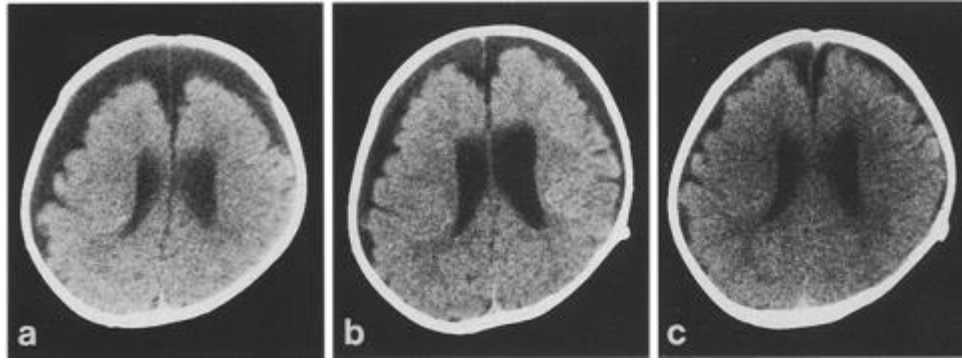


*Figure 7. Top: A subdural-peritoneal shunt system with a single-piece design. It consists of three parts: 1) Proximal catheter, 2) Flushing device, and 3) Distal catheter with a slit valve (marked by arrowheads). Notice the large catheter size and the absence of connectors in the large flushing device (indicated by arrows). Bottom: A ventriculoperitoneal shunt system, which is typically used in subdural-peritoneal shunting procedures.*

To install this shunt system, a small hole is made in the skull, and the space where the hematoma is located is washed out with a saline solution. Then, a space between layers of tissue on the scalp is carefully opened to put in the flushing device. After that, the procedure is similar to what's done for standard ventriculoperitoneal shunting with a one-piece design. After the surgery, the flushing device is pumped every day. Usually, about 2 months later, a CT scan is done to make sure the hematoma has gone away, and then the subdural-peritoneal shunt system can be removed.

## **Illustrative Case Report: Simplified Explanation**

A 4-month-old boy, previously healthy, was brought to Tokyo Metropolitan Fuchu Hospital's Pediatrics Department because his head was growing too quickly and his fontanel (soft spot on his head) felt tight. Doctors discovered fluid buildup around his brain, called bilateral subdural collection, during a CT scan. The fluid was thicker than normal cerebrospinal fluid and was causing pressure on his brain, resulting in a condition called chronic subdural hematoma. To treat this, doctors performed several procedures to drain the fluid over two weeks, but the hematoma kept growing.



*Figure 8 shows a series of CT scans: a) Before the operation, b) 7 days after the operation, c) 32 days after the operation.*

To solve this problem without raising pressure inside the skull, the boy had surgery to insert a special shunt system on one side of his head. This system helped drain the excess fluid away from his brain and into his abdomen. After the surgery, CT scans showed that the hematoma was getting smaller, and after a month, it almost disappeared completely. Two months later, when the hematoma was gone, the shunt was removed. Follow-up checkups revealed no more problems with his head, and six months later, he was developing normally with no signs of brain damage.

## **Discussion**

Deciding when to operate on infants with chronic subdural hematoma is based on whether they show signs of increased pressure inside the skull. However, it can be tricky to decide if surgery is needed when the hematoma is large but there are no obvious signs of pressure. Some babies with smaller heads might not need surgery even with a large hematoma because their skull can compensate for the pressure. On the other hand, babies with larger heads might not show symptoms even if they have pressure inside their skull. Also, parents and doctors might not notice when pressure inside the skull comes and goes. Some experts think that babies with fluid buildup outside their brain might get acute subdural hematoma even from minor head injuries.

Sometimes, a small hematoma can grow larger and cause problems with a baby's development. Because of these reasons, the author believes it's better to operate on babies with very large hematomas, even if they don't seem to have pressure inside their skull. However, using a regular shunt system for this type of surgery can be tricky because the fluid collected around the brain has a lot of protein and blood, which can clog up the shunt. To solve this problem, the author developed a special shunt system that includes a large flushing device without any extra connectors. This new system allows doctors to drain the hematoma more effectively. While there's not much experience with this new system yet, it seems to be the best option for treating chronic subdural hematoma in babies without pressure inside their skull.

## **Conclusion**

In conclusion, the treatment of infantile chronic subdural hematoma presents unique challenges for pediatric neurosurgeons. The decision to operate often hinges on whether the baby shows signs of increased pressure inside the skull. However, determining this can be difficult, especially when the baby's head size doesn't necessarily match the severity of the hematoma. Additionally, the intermittent nature of intracranial hypertension and the potential for complications from even minor head injuries further complicate treatment decisions.

Dr. Nobuhiko Aoki has played a significant role in addressing these challenges. Through his research and innovation, he has developed a specialized subdural-peritoneal shunt system designed to effectively drain large hematomas, even in the absence of overt intracranial hypertension. This novel system incorporates a large flushing device without connectors, offering a promising solution to the issue of shunt malfunction due to the high protein and blood content of subdural fluid.

While further research and experience with this new shunt system are needed, early results suggest it may offer a reliable treatment option for infantile chronic subdural hematoma. By providing a means to aggressively drain hematomas and minimize complications, Dr. Aoki's contributions have the potential to significantly improve outcomes for infants with this challenging condition. As the field continues to evolve, the development and refinement of innovative techniques such as this will be crucial in advancing pediatric neurosurgery and enhancing patient care.

# Chapter 4

## Management of Intraventricular Hemorrhages

### **Treatment Strategies for Intraventricular Hemorrhage**

Treatment strategies for intraventricular hemorrhage (IVH) aim to manage the underlying cause of bleeding while preventing complications and promoting recovery. In plain text, these strategies typically involve a combination of medical interventions and supportive care. Initial management often focuses on stabilizing the patient, ensuring adequate oxygenation, blood pressure control, and maintaining cerebral perfusion pressure within a normal range. In severe cases, surgical intervention may be necessary to evacuate the blood clot and relieve pressure on the brain. Additionally, medications such as osmotic diuretics may be used to reduce cerebral edema and intracranial pressure.

In some instances, clotting factors or platelet transfusions may be administered to address coagulopathy and prevent further bleeding. Close monitoring in an intensive care setting is essential to promptly identify and manage complications such as hydrocephalus, seizures, or infection. Rehabilitation services, including physical therapy, occupational therapy, and speech therapy, may also be initiated to help patients regain lost function and improve their quality of life. Overall, the treatment approach for IVH is tailored to the individual patient's condition, taking into account factors such as the severity of bleeding, underlying health issues, and potential risk factors.

### **Percutaneous Techniques in Neurosurgery**

Percutaneous techniques in neurosurgery involve procedures that are performed through the skin without the need for traditional open surgery. In plain text, these techniques often utilize specialized instruments and imaging guidance to access and treat various neurological conditions. One common application of percutaneous neurosurgery is in the management of pain, particularly chronic pain conditions such as trigeminal neuralgia or chronic back pain. Procedures like percutaneous radiofrequency ablation or percutaneous balloon compression can be used to selectively target and disrupt pain signals in the nerves, providing relief to patients who have not responded to conservative treatments. Additionally, percutaneous techniques are also employed in the treatment of certain types of brain tumors or vascular malformations.

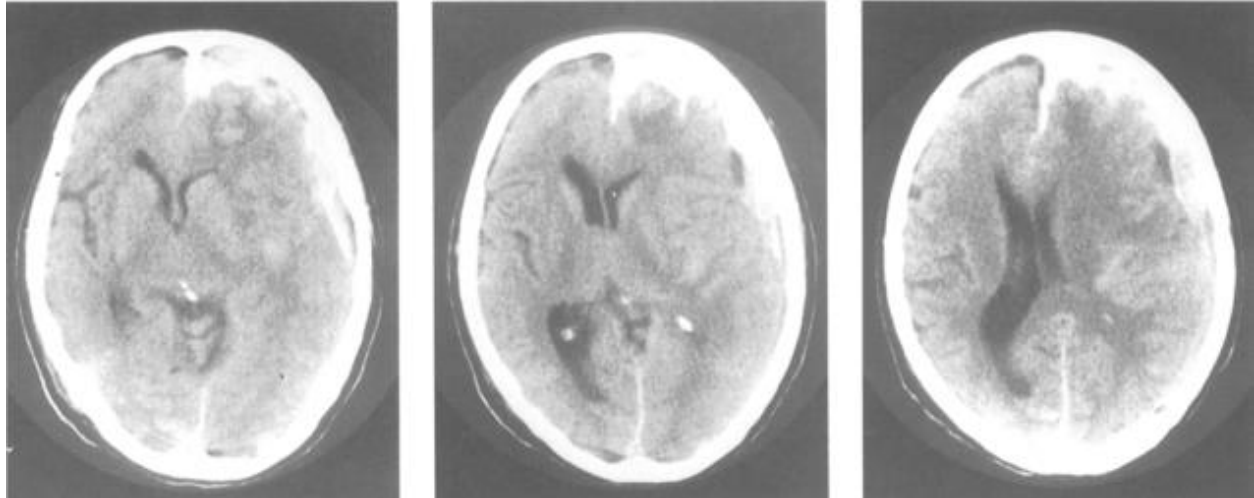
For example, percutaneous embolization may be used to selectively block blood flow to abnormal blood vessels, reducing the risk of bleeding or alleviating symptoms associated with vascular lesions. These minimally invasive approaches offer several advantages over traditional open surgery, including shorter recovery times, reduced risk of complications, and often can be performed on an outpatient basis. However, they require expertise in image-guided procedures and careful patient selection to ensure optimal outcomes.

## **Successful Treatment of Acute Subdural Hematoma in an Elderly Patient Utilizing Percutaneous Subdural Tapping**

Early surgical intervention plays a critical role in preventing lasting damage to the brainstem in individuals with acute traumatic subdural hematoma. Notably, Nobuhiko Aoki, one of the authors, has extensive experience in employing percutaneous subdural tapping for treating acute subdural hematoma in infants and chronic cases in adults. In a recent case, the authors successfully utilized percutaneous subdural tapping in an elderly patient with acute traumatic subdural hematoma, while preparing for a craniotomy. This innovative approach led to the effective removal of the hematoma. This experience underscores the potential utility of trial subdural tapping as a treatment option for acute subdural hematoma in elderly patients with cerebral contusion, prior to resorting to craniotomy.

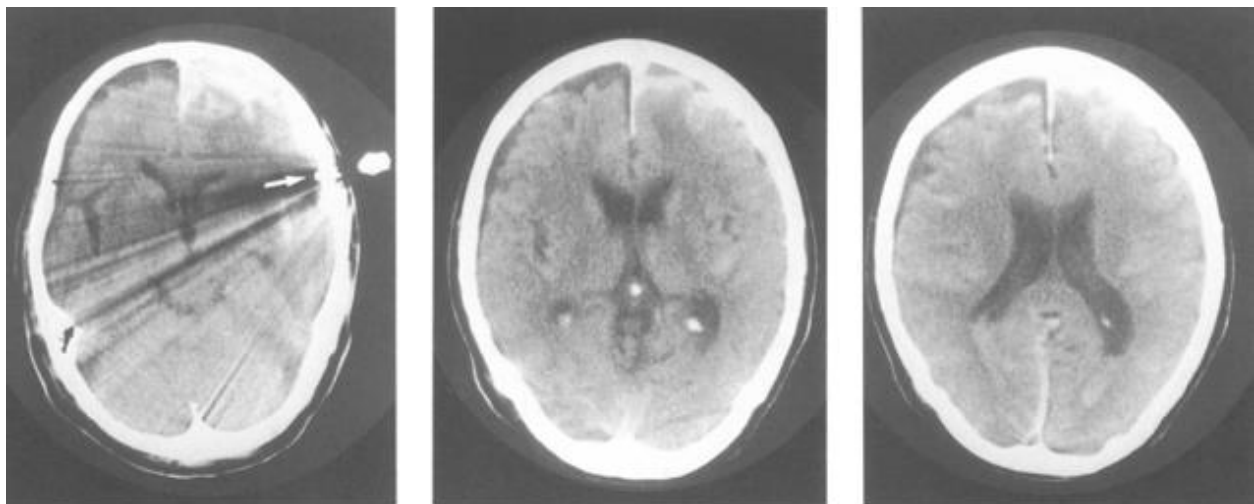
### **Case Report**

An 87-year-old man fell from a low height and hit his head at 9 a.m. on June 7, 1990. He didn't lose consciousness but was taken to a nearby hospital, where CT scans showed bleeding inside his head. Later that day, he was transferred to our hospital. He had a history of a previous stroke that caused temporary weakness on one side of his body seven years ago. When he arrived, he was awake but had a persistent headache. CT scans revealed bleeding on one side of his brain and fluid buildup on the other side, but his brain's central line wasn't shifted. He was treated without surgery. The next morning, he started vomiting frequently and became less responsive.



*Figure 1 shows CT scans taken 34 hours after the injury. It reveals acute bleeding on the left side of the brain and a bruise on the front left part. There's a noticeable shift of the brain's central line towards the right side.*

Emergency CT scans showed more bleeding on one side of his brain, a bruise on the front of his brain, and his central line shifted. The increase in bleeding was making him less conscious, so we thought about doing emergency surgery. However, before the surgery, we tried something new. We used a needle to drain some of the blood from the bruised area on the front of his brain. After we drained about 30 ml of blood, he started responding to us. We decided to keep draining more blood. Over the next 12 hours, we drained 200 ml of bloody fluid. By then, he was fully awake again, and CT scans showed that the bleeding had reduced a lot, and his brain's central line had shifted back to the middle.

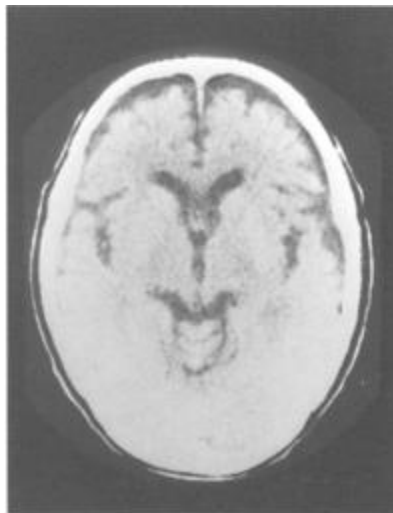


*Figure 2 shows CT scans taken 12 hours after starting to drain the blood from the brain using a needle inserted into the space between the brain and the covering of the brain (the subdural space). The scans indicate a clear decrease in the amount of blood outside the brain. While the bruise on the brain remained the same, the shift of the brain's central line almost disappeared.*

The bruise on his brain didn't change. We continued to monitor him with more CT scans, and the bleeding didn't come back. He was able to go home 12 days later, but he had some trouble with speaking and moving, which got better over time.

## **Discussion**

Usually, when adults have a type of brain bleeding called acute traumatic subdural hematoma, it's made of clots, so doctors don't usually think about using a method called subdural tapping to treat it. However, in some cases where people have had surgery to remove this type of bleeding, we noticed that the bleeding was more like a liquid or partially liquid. We've noticed this more often in older patients who have also hit their heads. In this particular patient, before the fall, he had a CT scan that showed fluid buildup and widening spaces in his brain. This suggests that in older patients, the bleeding might mix with the fluid in the brain, making it more like a liquid. This is important because sometimes, when we see dark spots on a CT scan, we think it's all clotted blood, but it might not be.



*Figure 3 displays a CT scan taken before the injury, illustrating fluid buildup between the brain's covering and the brain itself, along with widened spaces surrounding the brain.*

It's important to act quickly when treating this kind of brain bleeding. Studies suggest that surgery should happen within 2.5 hours of the injury to give the best chance of recovery. So, even if we can't do the full surgery right away, draining some of the bleeding using subdural tapping before surgery can still help. We've also found from treating other types of brain bleeding that subdural tapping is a simple and reliable method. We believe it can be helpful for treating acute subdural hematoma too.

## **A Novel Therapeutic Approach for Chronic Subdural Hematoma in Adults: Hematoma Replacement with Oxygen via Percutaneous Subdural Tapping**


For a long time, the go-to treatment for chronic subdural hematoma in adults has been a surgical procedure called burrhole craniostomy, where a small hole is made in the skull to drain the blood. This is usually done under local or general anesthesia. However, with the introduction of computed tomographic (CT) scanning, treating this condition became easier and less invasive. Since 1978, Nobuhiko Aoki, a prominent author in this field, has been using a method called percutaneous subdural tapping to manage chronic subdural hematoma. He emphasized the importance of thoroughly flushing out the area with saline solution to prevent the hematoma from coming back.

However, despite this approach being adopted by other neurosurgeons, some patients experienced a recurrence of the hematoma due to inadequate flushing. To address this issue, Aoki started trying a new treatment approach in 1984. Instead of just flushing the area with saline, he began replacing the hematoma with oxygen, believing it could be a simpler and more reliable method to prevent recurrence. After an initial report on this method, he further refined the technique and tools and treated 40 patients using this oxygen replacement approach. In this study, we'll look at the results of this procedure and discuss why it might be a safer option.

### **Clinical Materials and Methods**

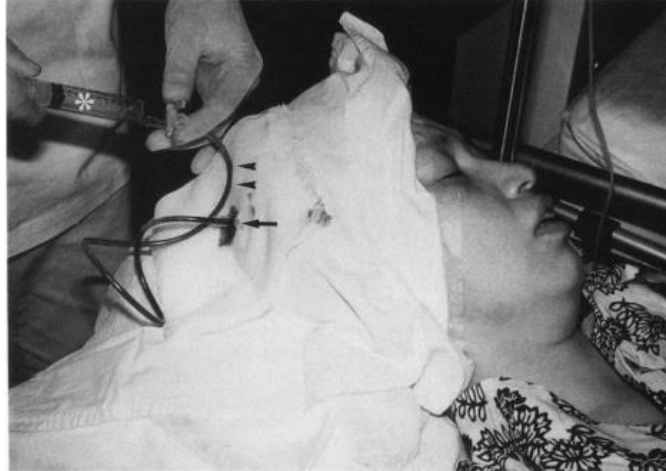
Between 1984 and 1991, 101 patients with chronic subdural hematoma underwent surgery at Tokyo Metropolitan Fuchu Hospital's Neurosurgery Department.

Among these patients, 40 were treated with a new method called replacement of the hematoma with oxygen via percutaneous subdural tapping. There wasn't a strict criteria for selecting patients for this procedure. The diagnosis was confirmed using CT scans, and the hematoma was confirmed during the tapping procedure. Out of these patients, 29 were men and 11 were women, aged between 38 to 87 years, with an average age of 68.5 years. The location of the hematoma varied, with 11 on the right side, 24 on the left, and 5 on both sides. Their preoperative conditions were classified into five categories using a neurological grading system. All patients were followed up for more than 6 months.



*Figure 4 shows the equipment used for subdural tapping, which was developed in 1990. At the top is the outer needle, in the middle is the inner needle, and at the bottom is the needle stylet.*

The procedure involves using a specially designed needle under local anesthesia. The needle is inserted through the skull using a twist-drill technique. If the needle gets blocked, it can be cleared using a stylet. The thickest part of the hematoma, as seen on CT scans, is then punctured. Once the liquid hematoma stops draining naturally, oxygen is slowly injected into the cavity, and an equal amount of hematoma is sucked out using a syringe. This process is repeated until no more hematoma can be obtained. To maintain equal pressure, the amount of oxygen injected is controlled. Finally, a closed system drainage is set up using an intravenous tube connected to a drainage bag, usually for around 30 minutes before the needle is removed, and the patient can get up.



*Figure 5 shows a photo taken during the process of replacing the hematoma with oxygen using percutaneous subdural tapping right next to the patient's bed. In the photo, you can see the outer needle of the subdural tapping equipment, marked with an arrow. There are also arrowheads pointing to the extension catheter, and an asterisk marking the syringe containing oxygen.*

## Results

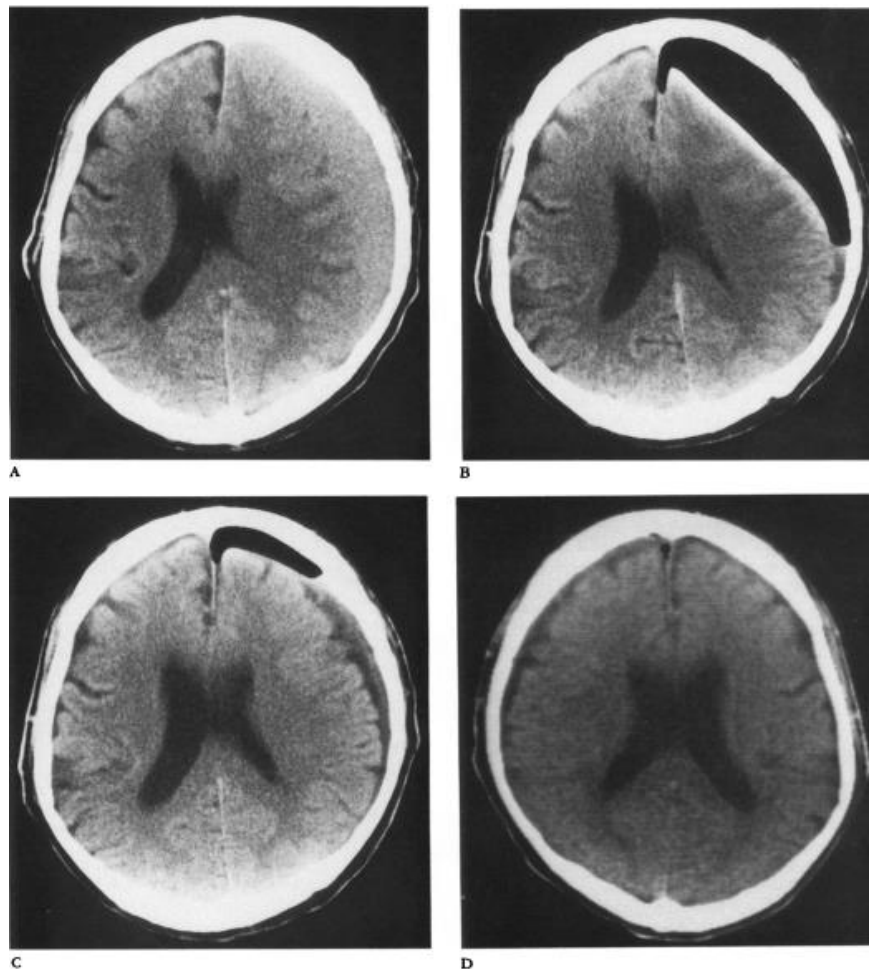
After treatment, all 40 patients showed good neurological recovery without any problems related to replacing the hematoma with oxygen. On average, 83 mL of oxygen was used to replace the hematoma, but this varied from 30 to 160 mL. During the follow-up period, two patients (5%) experienced a recurrence of symptoms on the 23rd and 40th days after surgery. One of these patients was treated again with oxygen replacement, while the other underwent a different procedure called burr-hole craniostomy with saline irrigation, and they didn't have any more recurrences. The table below shows the patients' preoperative neurological conditions and the outcomes of their treatment.

*Table 1 summarizes the outcomes of treating 40 patients with chronic subdural hematoma by replacing the hematoma with oxygen using percutaneous subdural tapping.*

Grade <sup>a</sup>	No. of patients	No. cured	No. with recurrence
0	0	0	0
1	6	6	0
2	19	18	1
3	11	11	0
4	4	3	1
<b>Total</b>	<b>40</b>	<b>38</b>	<b>2 (5%)</b>

## Discussion

The main goal in treating chronic subdural hematoma is to completely remove the blood, which helps the body naturally heal the area. The method we used aimed to completely remove the hematoma, which was confirmed by immediate CT scans after treatment. This method showed good results, with only a 5% recurrence rate in our series. Some surgeons may worry that tapping into the space around the brain might damage the brain or its blood vessels, especially if the blood has collected near the surface. However, in our experience, this method is safe when dealing with typical, dense hematomas like the ones we treated. The needle we use is only slightly longer than the thickness of the skull, so there's minimal risk. We prefer using oxygen to replace the hematoma because it's safer and based on our experience with other procedures.



*Figure 6 shows a series of CT scans taken before and after replacing the hematoma with oxygen. (A) Before the surgery. (B) Right after the surgery. (C) Two days after the surgery. (D) Eleven days after the surgery.*

When comparing our method of replacing the hematoma with oxygen using percutaneous subdural tapping to the standard burr-hole craniostomy with saline irrigation, we believe our method is better because it's simpler and less invasive. Burr-hole craniostomy can sometimes cause complications like intracerebral hematoma due to sudden pressure changes, but our method avoids this. With our method, there's also less risk of injuring the inner layers of the brain or allowing air to enter the brain's spaces, which can lead to other problems. Additionally, the gas we use stays only in the hematoma area, which is different from other conditions where gas might collect in other parts of the brain.

There's another less invasive method called twist-drill craniostomy with closed-system drainage, but our method is quicker and doesn't require the patient to lie down for as long. We believe that replacing the hematoma with oxygen using percutaneous subdural tapping is a good alternative to other procedures, especially for older patients who might not be in the best health.

## **Computed Tomography Findings Immediately Following Replacement of Hematoma with Oxygen via Percutaneous Subdural Tapping for the Treatment of Chronic Subdural Hematoma in Adults**

With the introduction of computed tomography (CT) scanning, doctors gained a more accurate way to locate bleeding inside the brain. This advancement led to simpler and less invasive treatment options for chronic subdural hematoma. Since 1978, Nobuhiko Aoki and his team have been using a method called percutaneous subdural tapping to manage chronic subdural hematoma in adult patients. One specific technique they've used more frequently involves replacing the hematoma with oxygen, which is known for being straightforward and reliable. However, there were concerns about this technique causing a condition called tension pneumocephalus, which shows up on CT scans after surgery. In this study, Aoki and his team examined the CT scans taken immediately after replacing the hematoma with oxygen. They wanted to see if they could distinguish between this method and tension pneumocephalus based on the CT features they observed.

### **Subjects and Methods**

Between 1985 and 1991, 36 adult patients with chronic subdural hematoma underwent a procedure where the hematoma was replaced with oxygen using percutaneous subdural tapping. For this study, we focused on 23 hematomas in twenty patients (three patients had hematomas on both sides), whose CT scans right after the treatment were available for review. The patients ranged in age from 33 to 86 years, with an average age of 66 years. There were 16 men and 4 women. We followed up with all patients for more than 6 months.

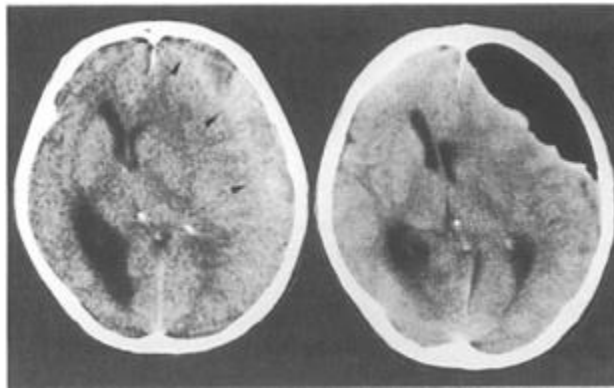
The procedure involves using a special needle, typically done at the patient's bedside under local anesthesia. After the liquid hematoma stops draining naturally, we slowly inject 10ml of oxygen

into the hematoma cavity. Then, we suck out 10ml of the liquid hematoma. We repeat this process until we can't get any more hematoma out. To make sure the pressure inside the hematoma cavity stays the same as the surrounding air, we control how much oxygen we inject and how much hematoma we suck out. Finally, we leave a short-term drainage (usually 30 minutes) to allow the oxygen and any remaining hematoma to drain out.

## Results

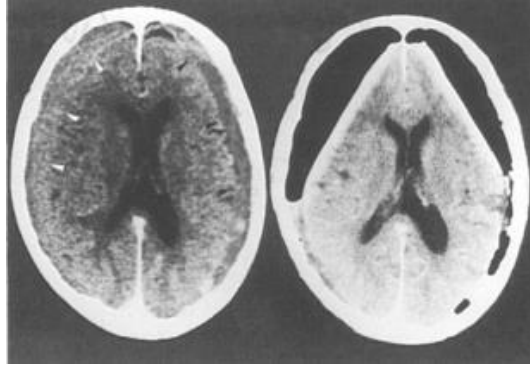
After the treatment, all 20 patients showed satisfactory neurological recovery without any problems related to replacing the hematoma with oxygen.

CT scans taken immediately after the procedure showed that most of the hematoma had been replaced by oxygen in all patients. The CT features were classified into two patterns based on where the oxygen was:

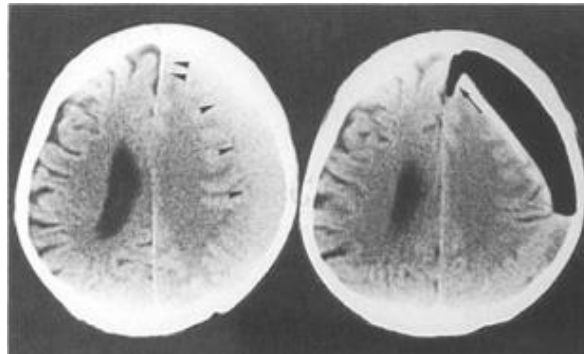

*Figure 7 shows two CT scans side by side. On the left is the preoperative scan, and on the right is the postoperative scan. This case is an example of a unilateral convexity type. You can see that the hematoma (marked by arrowheads) has been completely replaced with oxygen in the postoperative scan. There's no sign of oxygen in the spaces around the brain, like the subarachnoid spaces or the subdural spaces beyond the hematoma cavity.*

- 1. Convexity type:** Oxygen was mainly seen over the outer surface of the brain (cerebral convexity).
- 2. Interhemispheric type:** Oxygen extended into the space between the two halves of the brain (interhemispheric space).



*Figure 8 displays two CT scans side by side. The one on the left is before the surgery, while the one on the right is after. This case is an example of a bilateral convexity type. In the postoperative scan, you can see that the hematoma (marked by arrowheads) has been completely replaced with oxygen.*



*Figure 9 shows two CT scans side by side. The one on the left is before the surgery, and the one on the right is after. This case is an example of an interhemispheric type. In the postoperative scan, you can see that the hematoma (marked by arrowheads) involves the space between the two halves of the brain (interhemispheric space). Additionally, oxygen can be seen in the same region (indicated by the arrow), demonstrating the characteristic feature of the peaking sign.*

No oxygen was found in the spaces between the brain and its covering (subdural spaces) or in the spaces around the brain (subarachnoid spaces). You can find more details about the CT features in Table 2.

*Table 2 shows how oxygen is distributed immediately after replacing chronic subdural hematoma. It categorizes the location of oxygen to help understand where it ends up in the brain after the procedure.*

Pattern of the location of oxygen	No. of haematomas
Convexity type	19
Interhemispheric type	4
Total	23

## **Discussion**

Tension pneumocephalus, where air collects inside the head after treating chronic subdural hematoma, is a known but rare complication. There are characteristic signs on CT scans that indicate tension pneumocephalus, such as the peaking sign and the Mt. Fuji sign. Recent studies found that tension pneumocephalus becomes a problem when air moves into spaces around the brain beyond the hematoma cavity.

To find a simple and reliable way to treat chronic subdural hematoma, we used a method called replacement of the hematoma with oxygen through percutaneous subdural tapping. While this method gave good results, some were concerned it might lead to tension pneumocephalus because of the large amount of gas seen on postoperative CT scans. Even though oxygen is absorbed more easily than air, our experience didn't show much difference in how it affected patients' recovery. In this study, we classified the CT features right after treatment into two types: convexity and interhemispheric. The interhemispheric type looked similar to the signs of tension pneumocephalus, but we found that in our cases, the oxygen stayed only inside the hematoma cavity and didn't move into other spaces around the brain.

The usual method of treating chronic subdural hematoma involves washing the hematoma cavity with saline solution, which can sometimes cause damage to the inner membrane, allowing air to move around the brain. With percutaneous subdural tapping, there's less risk of damaging the inner membrane because the needle stays just beneath the outer membrane of the hematoma cavity. This means there's less chance of tension pneumocephalus developing, making the procedure safer.

In summary, the CT features after replacing the hematoma with oxygen can look similar to tension pneumocephalus, but because oxygen is absorbed easily and because our tapping method keeps the oxygen contained, there's less risk of complications like tension pneumocephalus occurring.

## **Conclusion**

In conclusion, the findings from our study shed light on the efficacy and safety of replacing chronic subdural hematoma with oxygen using percutaneous subdural tapping, as pioneered by Nobuhiko Aoki and his team. While tension pneumocephalus is a known complication following treatment

for chronic subdural hematoma, our research suggests that this innovative method significantly reduces the risk of such complications.

By carefully examining CT scans taken immediately after the procedure, we observed that the oxygen remained confined within the hematoma cavity, without migrating into other spaces around the brain. This is in contrast to tension pneumocephalus, where air can move into these spaces and cause problems. Additionally, our technique minimizes the risk of damaging the inner membrane of the hematoma cavity, further ensuring the safety of the procedure. Overall, the results of our study support the use of percutaneous subdural tapping with oxygen replacement as a simple, reliable, and safe treatment option for chronic subdural hematoma in adults.

# Chapter 5

## Acute Subdural Hematomas: Challenges and Innovations

### **Percutaneous Subdural Tapping in Elderly Patients**

Percutaneous Subdural Tapping, also known as subdural puncture or subdural tap, is a medical procedure used primarily in elderly patients to alleviate symptoms associated with subdural hematomas. Subdural hematomas are collections of blood that accumulate between the brain's surface and its outermost covering, the dura mater. In this procedure, a small hole is made through the skull to drain the excess blood that has accumulated in the subdural space, relieving pressure on the brain. This is typically done using a needle inserted through the skin and skull into the subdural space under imaging guidance such as CT or ultrasound. The procedure is minimally invasive and can be performed at the bedside under local anesthesia. It's often considered when other treatments like medications or observation aren't sufficient or feasible. It aims to reduce symptoms like headache, confusion, weakness, or difficulty walking that can arise from the pressure of the hematoma on the brain. Subdural tapping can significantly improve quality of life and functional outcomes in elderly patients suffering from subdural hematomas.

### **Chronic Subdural Hematoma: New Therapeutic Approaches**

Chronic Subdural Hematoma refers to a condition where blood collects between the brain's surface and its outer layer over a long period, usually weeks to months. New therapeutic approaches are emerging to better manage this condition. One such approach involves minimally invasive procedures like Burr hole surgery or endoscopic evacuation to remove the accumulated blood and relieve pressure on the brain. Another promising avenue is the use of medications like tranexamic acid to prevent further bleeding and promote clot stability. Additionally, studies are exploring the role of factors like patient positioning, drainage techniques, and post-operative care protocols to optimize outcomes and reduce recurrence rates. These advancements aim to improve the effectiveness and safety of treatment for chronic subdural hematomas, particularly in elderly patients who are more prone to this condition.

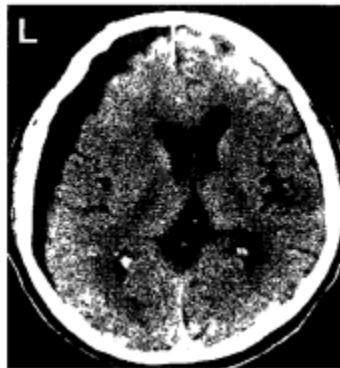
### **Progression of Chronic Subdural Hematoma following Burr-Hole Exploration for Subdural Effusion**

Over the years, advancements in medical imaging, particularly through computed tomographic (CT) scanning, have provided crucial insights into the development of chronic subdural hematoma (CSDH). Notably, the work of Nobuhiko Aoki has contributed significantly to our understanding of this condition. CSDH typically arises from a preexisting subdural effusion, where a capsule forms around the fluid cavity. This encapsulation sets the stage for repeated hemorrhages into the space, leading to the accumulation of blood and the characteristic features of CSDH. However, there remains debate within the medical community regarding whether the presence of blood in the subdural effusion is an indispensable prerequisite for the formation of CSDH.

In this chapter, we present a compelling case study that sheds light on this topic. The patient, who initially presented with neck pain following mild head trauma, exhibited signs of subdural effusion. Subsequent burr-hole exploration revealed a progression from subdural effusion to the development of CSDH, offering valuable insights into the pathogenesis of this condition. Through this case study, we aim to deepen our understanding of CSDH evolution and its implications for clinical management.

## Case Report

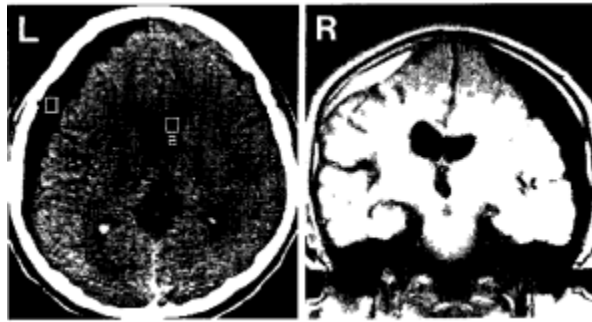
A 57-year-old man fell down some stairs and hit the middle part of his head on August 22, 1991. He didn't lose consciousness but felt neck pain when he went to the hospital on September 2. A CT scan showed fluid buildup on the left side of his brain. Even though he didn't show any neurological problems, he went to the Neurosurgery Department at Tokyo Metropolitan Fuchu Hospital for more tests on September 18.



*Figure 1 shows a CT scan taken 27 days after a minor head injury, revealing fluid buildup on the left side of the brain.*

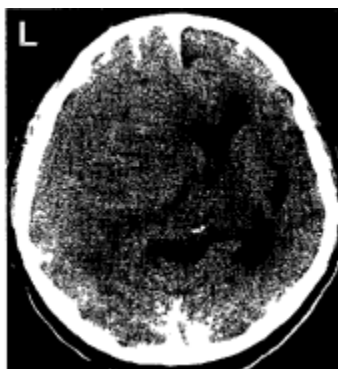
Doctors didn't find anything unusual in his neurological exam, but the CT scan still showed fluid on the left side, pushing some brain structures to the right a little. He didn't have any significant

medical history related to this issue, so they decided to keep an eye on him without doing surgery. But on October 31, he came back to the clinic complaining of feeling tired easily. The CT scan looked the same as before. Then, on November 28, he returned again feeling tired and depressed. The CT scan showed a new thin layer of blood on the right side, but the fluid on the left still looked the same. A special type of MRI scan showed that the fluid was similar to the normal brain fluid.



*Figure 2 displays a CT scan (on the left) and a T1-weighted MR image (on the right) taken 98 days after the injury. It shows fluid buildup without an increase in volume on the left side, and the appearance of a thin layer of blood between the brain and its outer covering (subdural hematoma) on the right side.*

Even though surgery wasn't necessary, the patient and his family insisted on it, so on November 28, doctors made a small hole in his skull to check things out. They found that the membrane covering his brain looked normal, and there was no pressure buildup inside his head. They didn't see any capsule forming around the fluid, which was clear and watery. After the surgery, he recovered well and left the hospital nine days later.



*Figure 3 shows a CT scan taken 139 days after the injury, which is 41 days after the burr-hole exploration surgery. It reveals typical signs of chronic subdural hematoma (CSDH) on the left side of the brain.*

However, by January 3, 1992, about six weeks after the surgery, his family noticed he was unsteady on his feet, confused, and had trouble controlling his bladder. They took him back to the hospital, where a CT scan showed a typical chronic subdural hematoma (CSDH) on the left side of his brain. He had another surgery on the same day to drain the blood and remove the capsule around it. Thankfully, he recovered smoothly after the surgery, and all his neurological problems went away.

## **Discussion**

In our patient, both CT and MRI scans showed fluid buildup in the subdural space, which stayed the same for three months. When doctors explored his skull with a burr hole, they didn't find a capsule forming around the brain, and the fluid they found didn't have any blood in it. However, six weeks later, he developed a typical chronic subdural hematoma (CSDH). Normally, when doctors make a cut in the membrane covering the brain, some blood leaks into the subdural space. This suggests that the CSDH in our patient might have happened because of blood mixing with the fluid during or after the surgery. This means that the CSDH didn't come from the fluid buildup itself but from the presence of blood mixing with it, which forms a capsule around the brain. Later, this capsule might have bled into the fluid space, causing the CSDH to develop. While not all cases with blood present will lead to a capsule and CSDH, this case suggests that blood might trigger this process.

Subdural effusion, where fluid collects between the brain and its outer covering, is often seen in CT scans after head injuries. However, whether surgery is needed for this condition is still debated among doctors. Patients who only have headaches are especially tricky to assess because it's hard to tell if the headache is from the fluid buildup or not. If surgery is needed for subdural effusion, doctors need to be very careful during the operation to stop any bleeding and prevent blood from getting into the space around the brain. Also, doctors should fully explain to the patient's family that there's a chance of developing CSDH after the surgery.

## **Percutaneous Subdural Tapping for the Management of Chronic Subdural Hematoma in Adult Patients**

With the widespread use of computed tomography (CT) scanning, doctors can now more easily detect chronic subdural hematoma (CSDH) even in patients with mild symptoms. This imaging technology has revolutionized how we understand and treat CSDH in adults. One prominent figure in this field is Nobuhiko Aoki, whose contributions have significantly advanced our knowledge. Over the past decade, adult patients with CSDH have increasingly undergone treatment using a technique called percutaneous subdural tapping.

A study involving 39 patients treated with this method emphasized the importance of thorough irrigation with saline to prevent recurrence. However, some patients experienced recurring hematomas due to inadequate irrigation, prompting the need for more effective solutions. In an

effort to address this issue and prevent recurrence, the author experimented with a new treatment approach involving the replacement of the hematoma with oxygen. This chapter explores the details of this innovative technique and presents sequential CT scans of six patients with CSDH who underwent this procedure. Through these case studies, we aim to elucidate the efficacy and reliability of this novel treatment method in managing CSDH in adult patients.

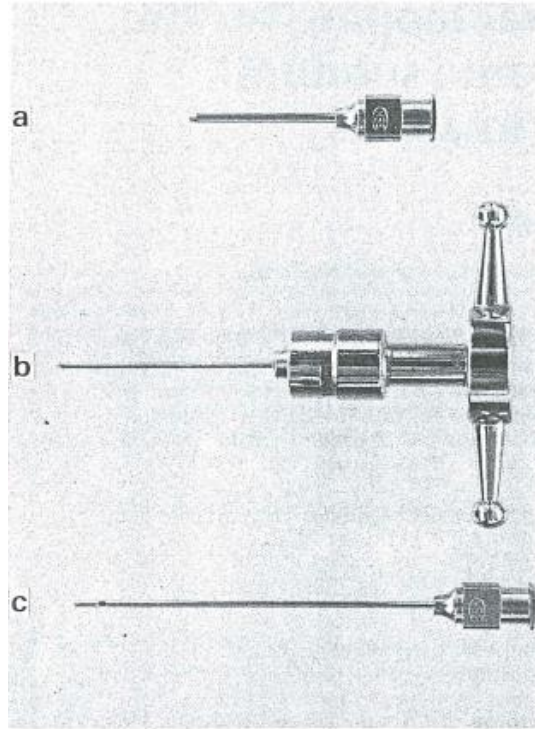
## Materials and Methods

From 1984 to 1985, six adult patients with chronic subdural hematoma (CSDH) underwent treatment involving percutaneous subdural tapping with oxygen replacement at the Department of Neurosurgery, Tokyo Metropolitan Fuchu Hospital. The group consisted of five men and one woman, aged between 45 and 74 years (average age: 60 years). CSDH was confirmed using CT scans, and patients with different conditions unrelated to CSDH were excluded from the study. Patients were categorized into four groups based on their neurological condition at the time of the procedure using the Tabaddor and Schalman grading system: mildly symptomatic (Group 1), lethargic (Group 2), stuporous (Group 3), and comatose (Group 4).

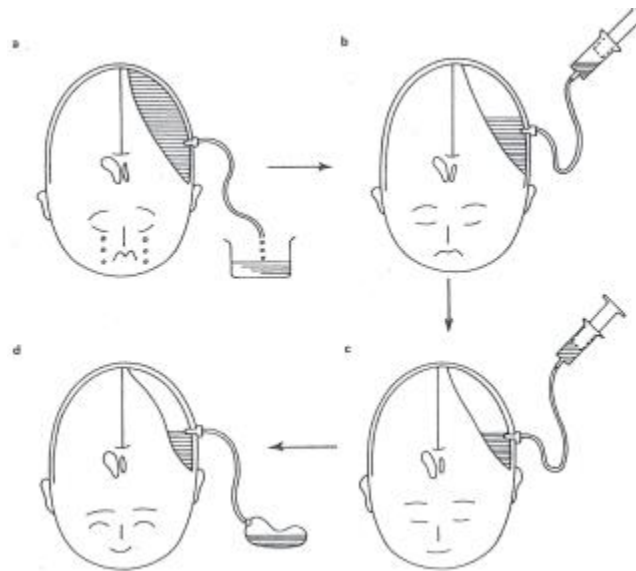
*Table 1: Overview of Six Cases Treated with Percutaneous Subdural Tapping Using Oxygen and Saline*

Case	Age/Sex	Group	Side	Evacuated haematoma (ml)	Replaced oxygen (ml)	Saline used for irrigation (ml)	Length of follow-up (month)	Clinical results
1	66/M	2	R	80	80	100	16	Cured, no recurrence
2	68/M	3	L	80	40	300	8	Cured, no recurrence
3	74/F	1	L(>R)	80	60	100	4	Cured, no recurrence
4	73/M	3	R	130	70	20	4	Cured, no recurrence
5	63/M	2	R(≅L)	80	80	30	3	Cured, no recurrence
6	45/M	4	L(>R)	85	70	60	2	Cured, no recurrence

The subdural tapping procedure was performed at the patient's bedside under local anesthesia using the Aoki subdural needle designed by the author. The thickest area of the hematoma identified on CT scans was targeted for tapping. Once the needle pierced the dura mater, the liquid hematoma drained out through a tube placed at the patient's bedside. Oxygen replacement was then introduced by injecting oxygen into the hematoma cavity and simultaneously aspirating the hematoma fluid. This process was repeated until no more hematoma could be obtained. The average amount of hematoma drained and evacuated was 80 to 130 ml, while the average amount of oxygen used for replacement was 40 to 80 ml. If the needle became blocked, it was cleared using a stylus needle, and saline was used for irrigation. After about an hour of drainage, the needle was removed. Most patients underwent a CT scan the day after the treatment, and follow-up scans were performed during outpatient visits.



**Figure 4: Components of the Subdural Tapping Needle Assembly: (a) Outer Needle; (b) Inner Needle; (c) Stylet Needle.**



**Figure 5: Steps of Subdural Tapping Method Using Oxygen and Saline: (a) Draining the Hematoma Naturally; (b) Introducing Oxygen; (c) Flushing with Saline; (d) Using Closed System Drainage for One Hour.**

## Results

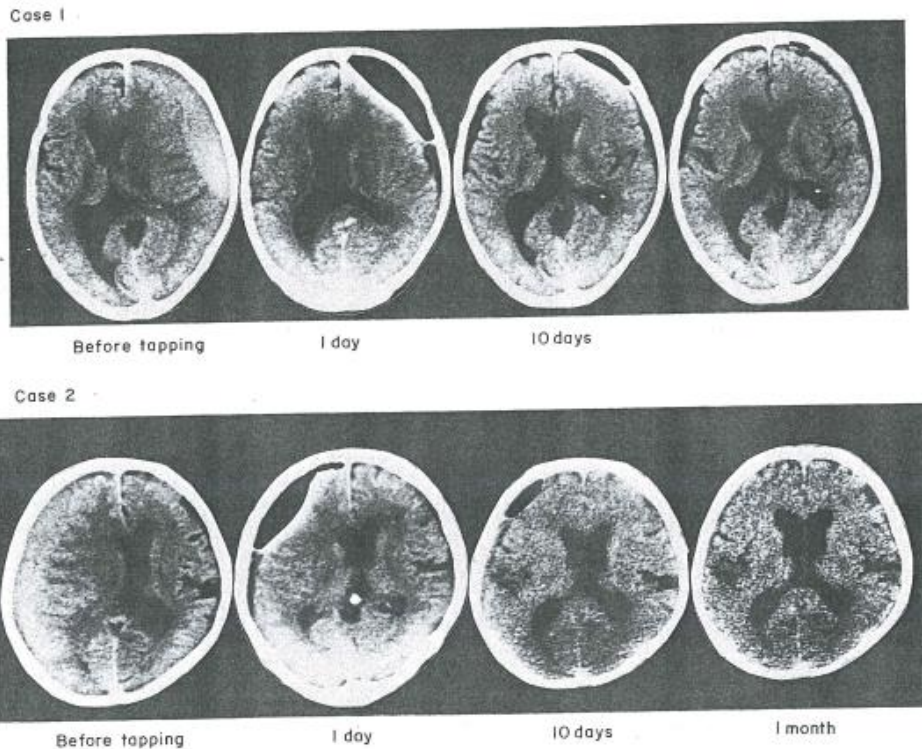
All six patients in the study became symptom-free after undergoing the procedure just once, as indicated in Table 2. None of them experienced a recurrence of symptoms during the follow-up period, which ranged from 2 to 16 months (with an average of 6 months). Follow-up CT scans conducted the day after the procedure showed a significant amount of gas buildup, which gradually decreased as the brain returned to its normal state. Although the exact time it took for the hematoma to disappear couldn't be determined due to irregular intervals between follow-up scans, only small residual collections were observed at various time points after the procedure. Interestingly, in two cases, the hematoma on the opposite side of the brain also disappeared without needing additional treatment. None of the patients experienced worsening symptoms or complications related to the procedure, including tapping, oxygen replacement, irrigation, and drainage.

*Table 2: Neurological Grading of Patients with Chronic Subdural Hematomas (Tabaddor and Shulman)*

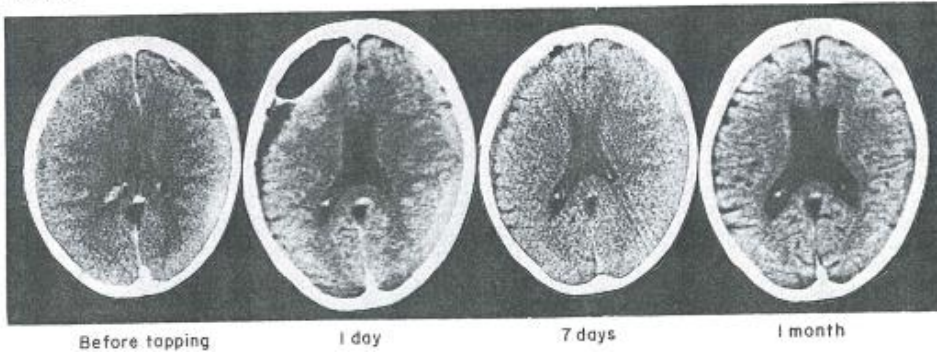
---

Group 1 = Mildly symptomatic with symptoms such as headache, seizure, or confusion
Group 2 = Lethargic with variable neurological deficit
Group 3 = Stuporous, but responding appropriately to painful stimuli
Group 4 = Comatose with decerebrate or decorticate posturing

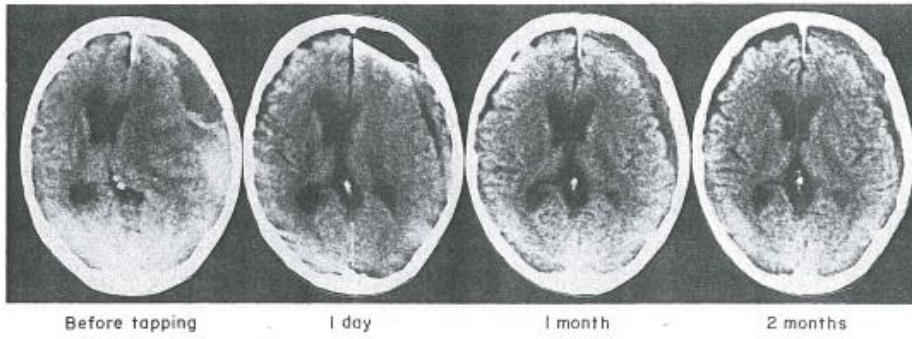
---



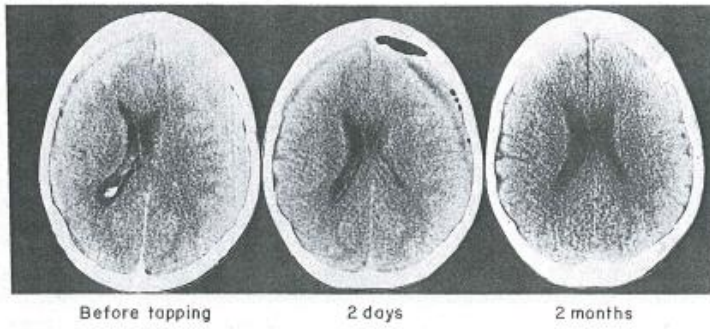
Case 3



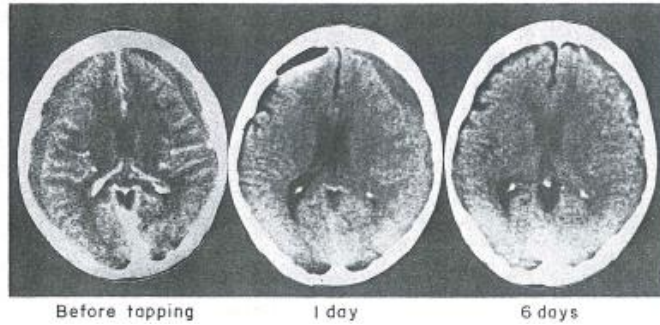
Case 4



Case 5



Case 6

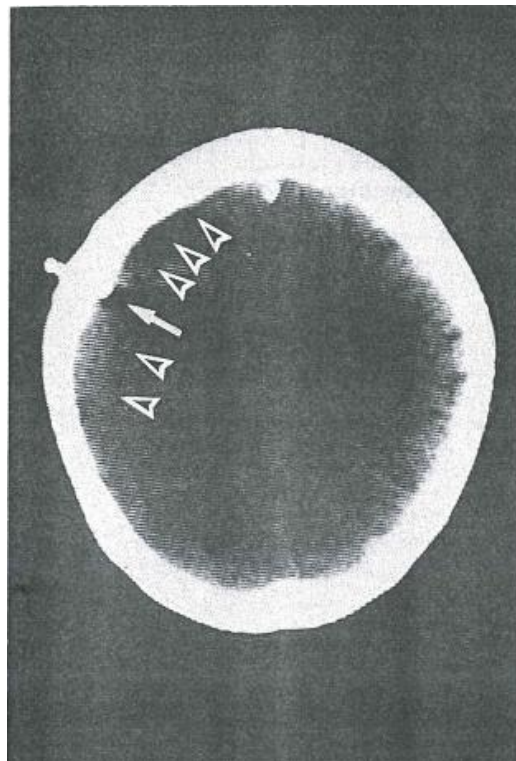


*Figure 6: Series of CT Scans in Six Patients.*

## Discussion

Tabaddor and Shulman found that using twist drill craniostomy and closed system drainage led to better outcomes compared to traditional burr hole drainage. Their approach is now widely accepted as the standard treatment. With the availability of CT scans, treating chronic subdural hematoma (CSDH) has become simpler.

For the past ten years, the author has been treating CSDH in adults using a minimally invasive method called percutaneous subdural tapping with a special needle they designed. Initially, patients were treated by draining the hematoma without irrigation, but recurrence was common. To address this, the author started irrigating the cavity with saline after draining the hematoma, which worked well. However, some patients treated by other neurosurgeons experienced recurrence due to inadequate irrigation. To improve irrigation, the author tried draining most of the hematoma first without creating negative pressure by replacing it with oxygen. Then, saline was used for further irrigation, resulting in more effective and faster treatment.



*Figure 7: CT Scan Displaying the Subdural Needle (indicated by the arrow) during Tapping. Arrowheads point to the subdural hematoma.*

Some neurosurgeons may worry that subdural tapping could harm the brain's cortex or bridging veins, especially in cases with shallow fluid buildup. However, when treating typical dense hematomas like those in this study, the risk is minimal. CT scans help accurately locate and safely tap the thickest part of the hematoma. The procedure's safety is confirmed by the CT images showing the needle during tapping.

Tension pneumocephalus, a condition where air gets trapped in the brain after surgery, is a concern with traditional methods. However, this procedure intentionally injects oxygen into the hematoma cavity, potentially raising concerns about tension pneumocephalus. To address this, oxygen is slowly introduced to prevent excessive pressure. Closed system drainage is then used to prevent air buildup. This approach helps avoid tension pneumocephalus.

Despite the needle extending only a few millimeters beneath the skull's inner surface, the risk of injuring the cortex or vessels is minimal. In this study, none of the patients experienced tension pneumocephalus or new bleeding. Compared to the standard burr hole drainage, which can cause significant pain during surgery, this procedure is preferred, especially for elderly patients prone to CSDH. It's less invasive, simpler, and more reliable.

## **Conclusion**

In conclusion, the treatment of chronic subdural hematoma (CSDH) has evolved significantly over the years, particularly with the introduction of minimally invasive techniques and advanced imaging technology. Nobuhiko Aoki's pioneering work in this field has contributed greatly to our understanding and management of CSDH in adult patients.

Through studies and innovations, such as percutaneous subdural tapping with oxygen replacement, Aoki has demonstrated the effectiveness of these techniques in achieving symptom relief and preventing recurrence in adult patients with CSDH. By refining the procedure over time and addressing challenges such as inadequate irrigation, Aoki has improved patient outcomes and reduced complications associated with traditional treatments.

The use of CT scans has allowed for precise localization and safe tapping of hematomas, minimizing the risk of cortical or vascular injury. Additionally, the intentional introduction of oxygen into the hematoma cavity has helped prevent tension pneumocephalus, a common complication associated with traditional surgical methods.

Overall, Aoki's approach offers a less invasive, simpler, and more reliable alternative to traditional burr hole drainage for treating CSDH in adult patients. This is especially beneficial for elderly patients who may experience significant pain during surgery. With its proven efficacy and safety profile, percutaneous subdural tapping with oxygen replacement stands as a valuable option for managing CSDH, improving patient outcomes, and enhancing the quality of care in neurosurgery.

# **Analysis of 18 Cases: Infantile Acute Subdural Hematohygroma - Clinical and Neuroimaging Perspectives**

In the realm of pediatric neurology, understanding rare conditions like Infantile Acute Subdural Hematohygroma (ASDHy) requires diligent investigation. Nobuhiko Aoki, a distinguished researcher in this field, has delved into this topic, shedding light on its clinical and neuroimaging intricacies.

Traditionally, studies on ASDHy in infants have been sparse, despite the availability of advanced diagnostic tools like magnetic resonance imaging (MRI). Aoki's work aims to fill this gap by comprehensively analyzing the clinical profiles and neuroimaging characteristics of ASDHy.

In this study, Aoki and colleagues examined 18 patients, all under the age of 2, diagnosed with ASDHy. The median age at diagnosis was approximately 3.8 months, with the majority being younger than 4 months. Notably, most cases manifested without any history of head trauma, challenging conventional assumptions about its etiology.

The presenting symptoms often included sudden convulsive seizures or repeated vomiting, prompting further investigation. Interestingly, retinal hemorrhage was a prevalent finding, occurring in the majority of cases.

Neuroimaging studies revealed distinct features, such as bilateral subdural fluid collection with higher intensity than cerebrospinal fluid on MRI. Additionally, benign enlargement of the subarachnoid space (BESS) and enlarged sylvian fissure (LSF) were common radiological findings, indicating structural vulnerabilities.

Despite the severity of the condition, the prognosis was surprisingly favorable in all cases, with conservative management being the primary approach. This suggests that ASDHy is a self-limiting disorder, albeit associated with retinal hemorrhage, emphasizing the importance of early detection and intervention.

Aoki's findings suggest that structural vulnerabilities, particularly LSF, may contribute to the pathogenesis of ASDHy. This theory posits that LSF could predispose infants to increased rotational forces within the brain, even with mild or unnoticed impacts.

Aoki's research underscores the significance of understanding ASDHy in infants, highlighting its unique clinical features and neuroimaging characteristics. By elucidating its pathogenesis, this study offers valuable insights into the management and prognosis of this rare neurological condition.

## **Introduction**

The medical community still hasn't fully understood acute subdural hematoxygroma (ASDHy) due to its unclear definition and limited research on how it develops. This makes its importance and how it affects people up for debate.

One way doctors can distinguish ASDHy from other brain conditions is by using MRI scans, which show fluid buildup outside the brain. But even with this technology, we're not entirely sure how ASDHy happens. The leading theory suggests it might start with tears in a thin membrane around the brain, causing fluid to leak into a space it shouldn't be in. However, we're still unsure if this happens because of a hit to the head or if it's a natural build-up of fluid in that area.

More people are becoming aware of ASDHy, and this has led to increased research into what causes it. To try to solve these mysteries, this study looked at cases from the past ten years to see if we can learn more about how ASDHy happens and what might trigger it.

## **Materials & Methods**

Between 2013 and 2023, doctors at Bethlehem Garden Hospital's Neurosurgery Department saw 51 babies under 2 years old with symptoms suggesting they might have a problem with blood and fluid building up around their brain. To understand this better, the doctors looked at all the information about these babies, including their medical scans like CT scans and MRI scans, as well as records of their interviews.

Out of these 51 babies, 18 were diagnosed with something called acute subdural hematoxygroma (ASDHy) after doctors carefully studied their medical history and brain scans. Advanced MRI scans, including special types like susceptibility-weighted imaging (SWI) and T2\* sequences, showed that these babies didn't have any damage to their brain tissue itself.

After their medical assessment, all these babies were sent to a special center where experts checked them over to make sure they hadn't been hurt on purpose, like with shaken baby syndrome or abusive head trauma. Babies with conditions that make them bleed more easily were also not included in this study.

ASDHy happens when a mix of blood and cerebrospinal fluid (or a fluid similar to it) gathers in the space around the brain, causing sudden symptoms. In this study, doctors also looked at something called benign enlargement of the subarachnoid space (BESS), which is when there's extra space between the brain and the skull. They defined it as at least 5 millimeters of space. They also defined a large sylvian fissure, which is a specific part of the brain, in a certain way.

## **Results**

### **Clinical Findings**

In this study, we examined 18 patients, consisting of eight males and ten females, with an average age at diagnosis of 3.8 months, ranging from 2 to 10 months. Most of these patients (83%) were under 4 months old. While four patients experienced symptoms after a minor fall, the majority (72%) had no history of head trauma.

All patients showed sudden symptoms, including convulsive seizures and repeated vomiting, with some experiencing both. About two patients needed subdural drainage due to poor seizure control or altered consciousness. Most patients (89%) were treated conservatively, leading to positive outcomes during follow-up examinations, which ranged from 3 months to 9 years and 2 months, averaging at 3 years and 5 months. Remarkably, none of the patients experienced a recurrence of the subdural fluid collection during the study period.

### **Neuroimaging Findings**

On MRI scans using FLAIR or SWI techniques, ASDHy appeared as a significant fluid collection between certain layers of the brain, showing higher intensity than normal cerebrospinal fluid. This condition was bilateral in all patients and covered both sides of the brain. In some cases, it was more pronounced on the right or left side, or approximately equal on both sides.

Benign enlargement of the subarachnoid space (BESS) was observed in 83% of patients, and all patients displayed a large sylvian fissure (LSF), with most cases (94%) being more prominent on the left side. MRI scans, including SWI and T2\* sequences, showed no signs of primary injury to the brain tissue or complex subdural hematoma.

For a detailed overview of patients' clinical profiles, please refer to Table 1.

Case No	Age (mos) M/F	Presenting signs & symptoms	History of trauma	Management	Retinal hemorrhage	Imaging findings			Outcome (follow-up)
						ASDHy	BESS	LSF	
1	10M	Seizure	Low fall	Conservative	None	Bilateral R>L	(+)	(+) L>R	GR 9y2m
2	3F	Vomiting, seizure	None	Conservative	Bilateral	Bilateral L=R	(+)	(+) L>R	GR 4y8m
3	7F	Seizure	Low fall	Conservative	Bilateral	Bilateral L=R	(+)	(+) L>R	GR 4y3m
4	2M	Vomiting, seizure, tense fontanel	None	Conservative	Bilateral	Bilateral R>L	(+)	(+) L>R	GR 4y3m
5	4F	Vomiting	Fall from bed (50 cm in height)	Conservative	Bilateral	Bilateral L=R	(-)	(+) L>R	GR 4y0m
6	5F	Seizure	None	Conservative	Bilateral	Bilateral L=R	(+)	(+) L>R	GR 4y0m
7	4F	Seizure	Fall from sister's hands (30 cm in height)	Subdural drainage	Bilateral	Bilateral L=R	(+)	(+) L>R	GR 3y7m
8	8M	Seizure	Low fall	Conservative	Bilateral	Bilateral L>R	(+)	(+) L>R	GR 3y7m
9	3M	Seizure	None	Conservative	Bilateral	Bilateral R>L	(-)	(+) L>R	GR 3y10m
10	2M	Vomiting	None	Conservative	Unilateral left	Bilateral L>R	(+)	(+) L>R	GR 10m
11	4F	Seizure	None	Conservative	None	Bilateral R>L	(+)	(+) L>R	GR 11m
12	3F	Seizure	None	Conservative	None	Bilateral L=R	(+)	(+) L>R	GR 9m
13	2M	Seizure	None	Conservative	None	Bilateral L=R	(+)	(+) L=R	GR 8m
14	4F	Vomiting	None	Subdural drainage	Unilateral right	Bilateral R>L	(-)	(+) L=R	GR 1y4m
15	3M	Seizure	None	Conservative	Bilateral	Bilateral R>L	(+)	(+) L>R	GR 4m
16	4F	Vomiting, seizure	None	Conservative	Unilateral right	Bilateral R>L	(+)	(+) L>R	GR 3m
17	3M	Seizure, macrocrania	None	Conservative	Bilateral	Bilateral R>L	(+)	(+) L>R	GR 3m
18	2F	Vomiting	None	Conservative	None	Bilateral R=L	(+)	(+) L>R	GR 1y

Abbreviations ASDHy: acute subdural hematoxygroma, BESS: benign enlargement of subarachnoid space LSF: large sylvian fissure GR: good recovery  
L: left R: right

## Case Series

### Case 1 (Patient 4)

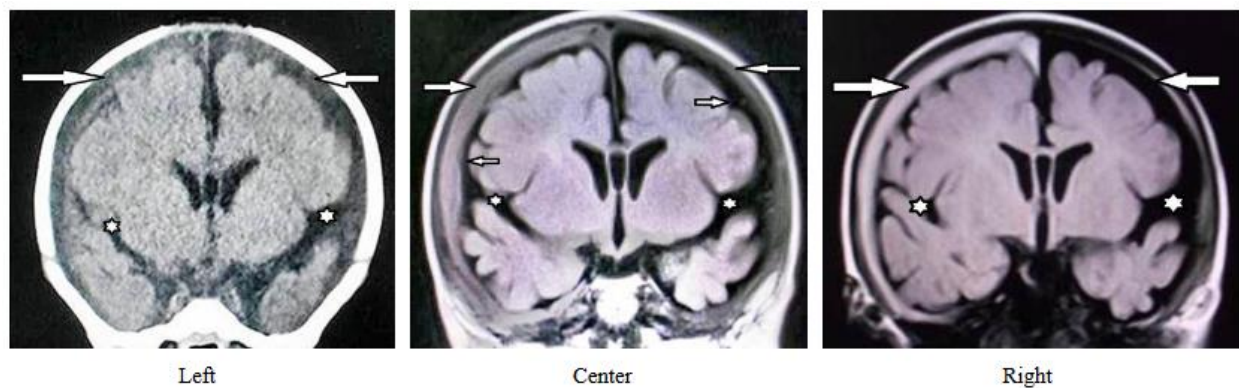
This case involves a 2-month-old baby boy who was born full-term and had no history of head injuries. He experienced two days of vomiting on and off, followed by generalized seizures. His family took him to the local hospital's emergency department, where doctors noticed that he seemed altered and his fontanel (soft spot on the top of the head) was tense.

The pediatrician at the hospital used a special scan called computed tomography (CT) to see inside the baby's head. The scan showed there was fluid collecting outside the brain, which is called subdural fluid collection (Figure 1, left).

During his stay at the hospital, an eye exam showed that he had bleeding in both of his retinas. After watching him for a while, the doctors determined that his condition wasn't caused by abuse.

His time at the hospital was relatively smooth, and on the fourth day, he had another type of scan called magnetic resonance imaging (MRI). This scan showed that the fluid collection was between the layers of tissue around his brain (Figure 1, right).

When he came back for a follow-up MRI 19 days later, the fluid collection had started to decrease, and there were no other problems with his brain tissue. Over the next five months, he continued to grow and develop normally, with no lasting effects on his brain or behavior.



*Figure 1. Case 1 (Patient No. 3), 2-month-old female. Left Image (CT scan, coronal view): When the patient arrived, the CT scan showed large fluid collections outside the brain on both sides. The fluid appeared slightly brighter on the right side compared to the cerebrospinal fluid (CSF). Additionally, there were noticeable large openings in the brain tissue known as sylvian fissures, which were more prominent on the right side than the left.*

*Center Image (MRI, fluid-attenuated inversion recovery, FLAIR, three days after onset): Three days later, an MRI showed that the fluid collections around the brain had a higher signal intensity compared to CSF, indicating the presence of acute subdural hematoxygroma (ASDHy). Benign enlargement of the subarachnoid space (BESS) was also observed, more pronounced on the right side. Again, large sylvian fissures were visible on both sides of the brain.*

*Right Image (MRI, FLAIR, 21 days after onset): Twenty-one days later, a follow-up MRI showed a decrease in the size of the fluid collections (ASDHy). The sylvian fissures remained large, particularly on the right side.*

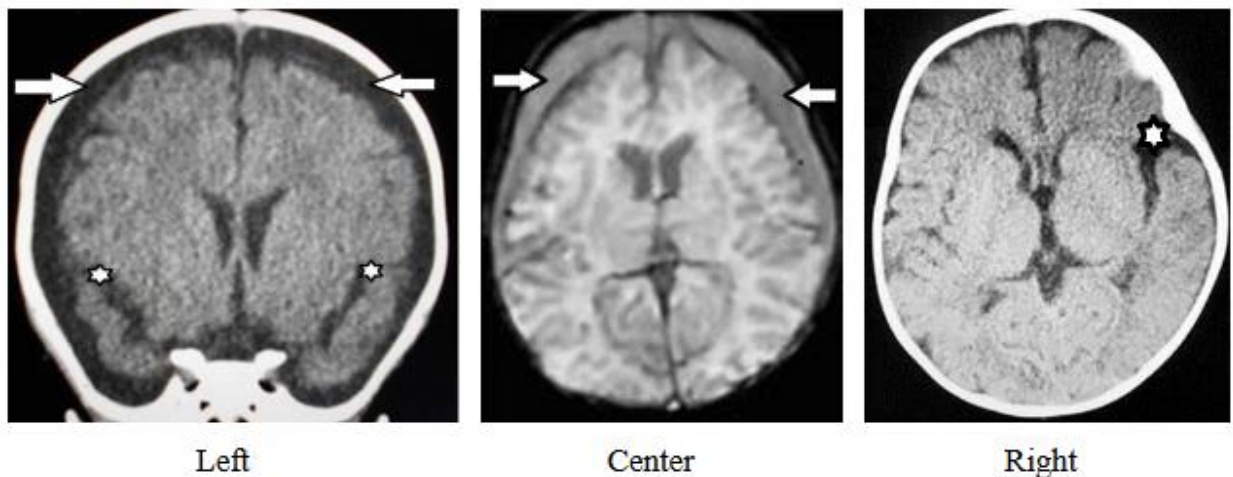
## Case 2 (Patient 5)

This case involves a 4-month-old baby girl who had previously had acute bronchiolitis when she was 2 months old. One day, she fell from her bed and hit the back of her head on a tatami mat. She started crying immediately and then vomited forcefully twice.

The next day, her family took her to the local hospital because she kept vomiting. Doctors noticed that her fontanel (soft spot on the top of her head) was tense, so they did a CT scan, which showed fluid collecting outside her brain (Figure 2, left). They also did an eye exam and found bleeding in both of her retinas.

She stayed in the hospital for more observation, and experts confirmed that her condition wasn't caused by abuse. Twelve days later, she had an MRI scan, which showed that the fluid around her brain had started to decrease (Figure 2, center).

During the two weeks she stayed in the hospital, she didn't have any symptoms, and eventually, she was allowed to go home. Over the next five months, she continued to grow and develop normally. Follow-up CT scans showed that the fluid around her brain had gone away completely (Figure 2, right).



**Figure 2. Case 2 (Patient No. 5), 4-month-old female**

**Left Image (CT scan, coronal view on admission):** The CT scan taken when the patient was admitted to the hospital shows large fluid collections outside the brain on both sides. These collections look similar to cerebrospinal fluid (CSF). Also visible are the large sylvian fissures on both sides of the brain.

**Center Image (MRI scan, susceptibility-weighted imaging, SWI, 12 days after onset):** Twelve days later, an MRI scan shows an area of increased signal intensity in the fluid collections around the brain compared to CSF. This indicates the presence of acute subdural hematoxygroma (ASDH<sub>y</sub>). No abnormalities were observed in other sequences of the MRI.

*Right Image (CT scan at post-onset month 5): Five months after the onset of symptoms, a follow-up CT scan shows that the fluid collections around the brain have disappeared, indicating resolution of ASDHy. However, there is still residual enlargement of the sylvian fissure on the left side.*

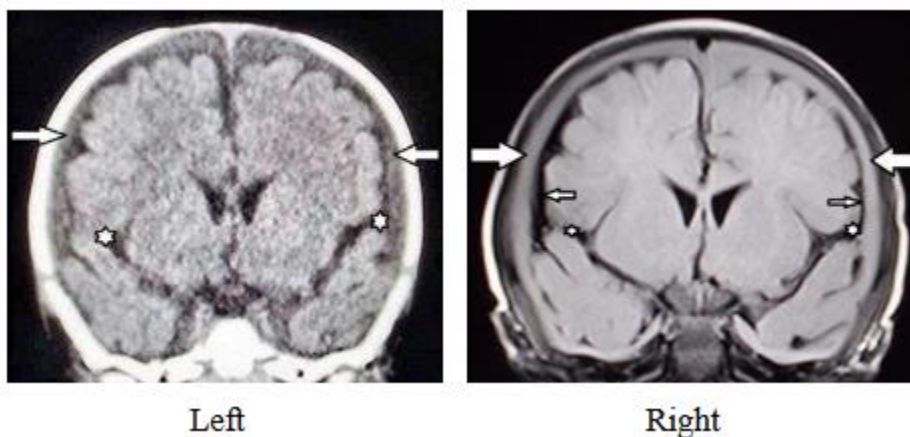
### **Case 3 (Patient 9)**

This case involves an 8-month-old baby boy with no significant medical history. One day, while his mother was changing his diapers, she noticed that he seemed dazed and was staring upwards. Soon after, he had a tonic convulsion, which is a type of seizure where the body stiffens suddenly.

His family rushed him to the local hospital's emergency department, where a doctor saw that he was having continuous seizures, a condition called status epilepticus. The doctor also noticed that his fontanel (soft spot on the top of the head) was tense. A CT scan done in the emergency revealed that there was fluid collecting around his brain on both sides (Figure 3, left).

Doctors gave him medicine to stop the seizures and decided to watch and wait to see how he would progress. By the second day, his seizures were under control with the help of anticonvulsant medication. An MRI scan done around this time showed that he still had fluid around his brain, and there were also some other changes in his brain structure (Figure 3, right). An eye exam showed bleeding in both of his retinas.

Four days later, he had fully recovered from his seizures and was allowed to go home with oral anticonvulsants. Twenty days after his seizures started, he was discharged from the hospital. During his time in the hospital, experts confirmed that his condition wasn't caused by abuse. A follow-up exam when he was 3 years and 1 month old showed that he was developing normally.



*Case 3 (Patient No. 9), 6-month-old male:*

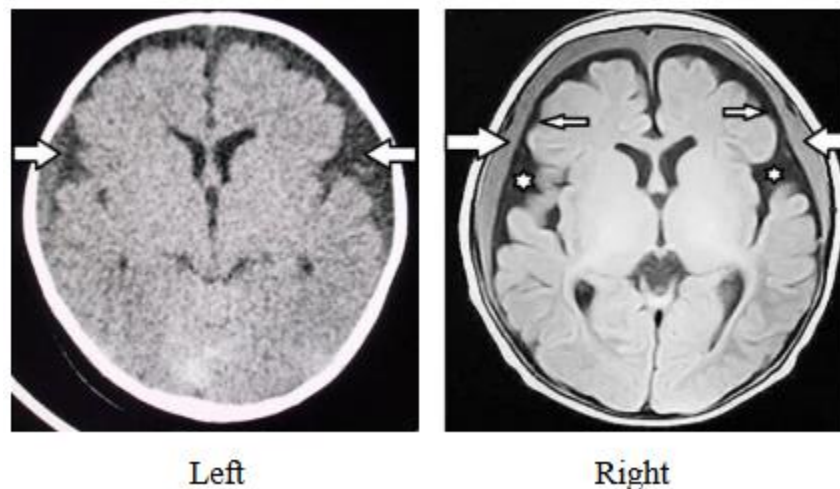
*Left Image (CT scan, coronal view on arrival): The CT scan taken when the patient arrived at the hospital shows fluid collections outside the brain on both sides. These collections appear slightly brighter than cerebrospinal fluid (CSF) in the lateral ventricles, indicating acute subdural hematomas (ASDH). Also visible are the large sylvian fissures on both sides of the brain, with the left side being slightly larger (stars).*

*Right Image (MRI scan, fluid-attenuated inversion recovery, FLAIR, coronal view, obtained 2 days later): Two days later, an MRI scan shows bilateral fluid collections around the brain (ASDHy). The sylvian fissures are again visible on both sides, with the left side being larger. Additionally, there is enlargement of the subarachnoid space (SAS), which is more pronounced on the left side (small arrows). No abnormalities were found in other sequences of the MRI.*

#### **Case 4 (Patient 13)**

This case involves a 2-month-old baby boy who was born without any complications and didn't have any major health issues before. One day, while he was breastfeeding at home, his family noticed that he started vomiting and had jerky movements in his right hand, similar to muscle twitches (they even caught it on video).

Concerned, they took him to the local hospital's emergency department. The pediatrician who examined him didn't find anything unusual.



*Figure 4. Case 4 (Patient No. 13), 2-month-old male.*

*Left Image (CT scan): This CT scan, taken when the patient arrived, shows fluid collections on both sides outside the brain (extra-axial). These collections are indicated by the arrows.*

*Right Image (MRI scan, fluid-attenuated inversion recovery, FLAIR, axial view): The MRI scan, specifically FLAIR sequence, reveals bilateral fluid collections around the brain (ASDHy), as indicated by the arrows.*

*Additionally, benign enlargement of the subarachnoid space (BESS) is visible (small arrows), along with enlargement of the sylvian fissures (LSF), highlighted by stars. Other sequences of the MRI did not show any abnormalities.*

While on the way home, the infant started experiencing jerky movements similar to muscle twitches and developed a fever. Concerned, the family took him back to the hospital where he was previously seen. A CT scan at the hospital revealed fluid collections outside the brain on both sides (Figure 4, left). On the same day, an MRI scan showed a large amount of fluid around the brain (ASDHy), along with benign enlargement of the subarachnoid space (BESS) and enlargement of

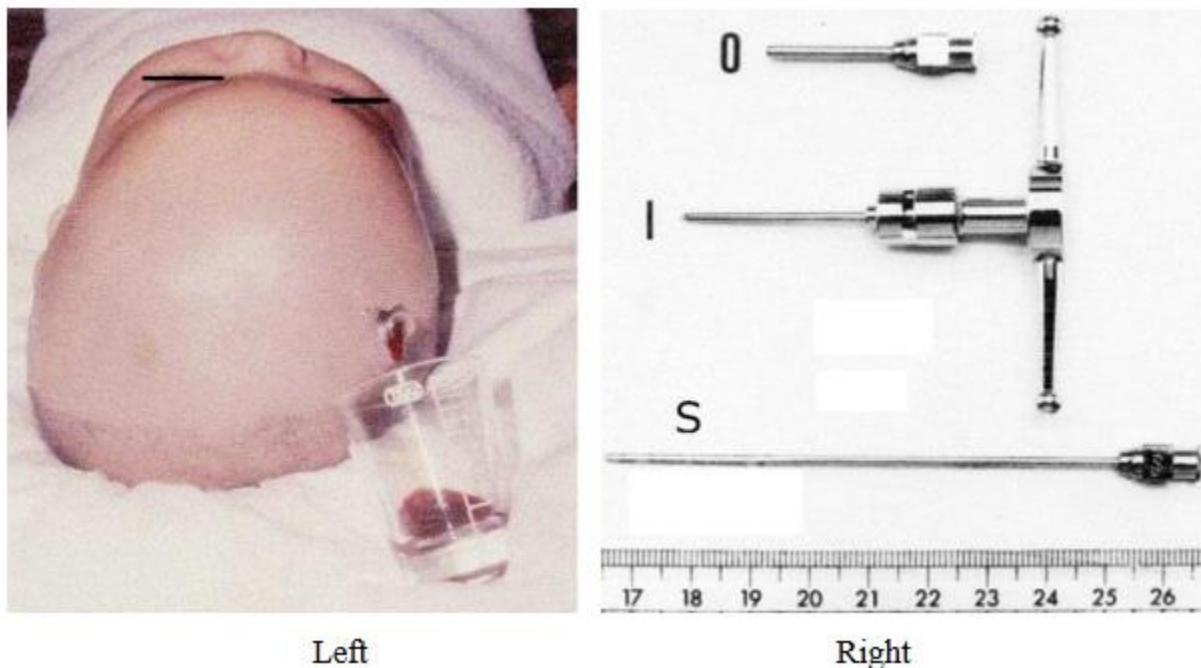
the sylvian fissures (LSF) on both sides (Figure 4, right). An eye examination didn't find any bleeding or other issues in the retina.

He stayed in the hospital for close observation, and experts confirmed that his condition wasn't caused by abuse. After his discharge, he was followed up at the outpatient clinic for 11 months, during which he reached normal developmental milestones.

## Discussion

### Clinical Presentation and Diagnosis

All the infants in this series showed signs like seizures and repeated vomiting, which helped doctors diagnose them with ASDHy. The way ASDHy presents, with seizures and retinal hemorrhages, is quite similar to another condition called infantile acute subdural hematoma (IASDH). Especially mild cases of IASDH, which also involve retinal hemorrhages and often recover without treatment, can be easily confused with ASDHy. (Figure 5).



*Figure 5. Percutaneous Subdural Tapping (not included in the case series).*

*Left Image: Subdural tapping was performed by inserting a needle through the skull directly into the largest part of the subdural hematoma. This procedure was done under local anesthesia, regardless of the location of cranial sutures.*

*Right Image: This image shows the three parts of the needle assembly used for percutaneous subdural tapping. It's called the Aoki subdural needle for infants, manufactured by Muraishi Iryoki Co., Ltd., Tokyo, Japan. If the drainage is blocked by a partially clotted hematoma, the obstruction of the outer needle can be released using a stylet needle. In the image, "O" stands for outer needle, "I" for inner needle, and "S" for stylet needle.*

### Differentiating from Abusive Head Trauma (AHT)

In cases of abusive head trauma (AHT), there's usually some injury directly to the brain tissue. However, in all the infants with ASDHy in this series, there was no injury to the brain tissue itself. In Japan, healthcare workers have a legal obligation to report any suspected cases of child abuse to a childcare center. All the infants in this series were reported to a childcare center, which ruled out AHT.

### **Imaging Challenges and Solutions**

When doctors first see large fluid collections outside the brain on a CT scan, it can be hard to tell if it's ASDHy or something else like benign enlargement of the subarachnoid space (BESS) or chronic subdural hematoma. However, using MRI, especially with FLAIR imaging, doctors can see if there are new membranes forming, which helps them tell the difference between chronic subdural hematoma and ASDHy. The exact cause of ASDHy in relation to BESS is not well understood, but it's believed that the stress on the arachnoid membrane and blood vessels in the enlarged subarachnoid space might play a role.

### **Mechanism of ASDHy Development**

ASDHy is thought to develop when the bridging veins in the subdural space are stretched due to the enlarged CSF spaces, making the person more prone to developing a subdural hematoma. The loose fixation of the temporal lobe at the middle cranial fossa and the sphenoid ridge allows for greater brain mobility. This increased mobility can lead to stretching of the bridging veins, causing them to rupture.

### **Management and Treatment**

ASDHy typically resolves on its own without causing any lasting damage, but in some cases, like Cases 1 and 3 in this series, surgery may be needed. If surgery isn't done quickly after signs of severe symptoms appear, permanent neurological damage can occur. For infants, less invasive treatments like percutaneous subdural tapping may be recommended. Additionally, even though most cases of ASDHy involve fluid collections on both sides of the brain, treating only one side may be enough to clear the fluid from both sides.

### **Significance of Left-Sided Sylvian Fissures (LSF)**

In this series, it was interesting to note that most patients had a left-sided enlargement of the sylvian fissure, even though ASDHy is usually more pronounced on the right side. This finding might provide some clues about why the arachnoid membranes and bridging veins rupture in patients with increased cranio-cerebral disproportion. The loose fixation of the temporal lobe and the

sphenoid ridge might allow for greater brain mobility, contributing to the stretching and rupture of the bridging veins.

## **Conclusion**

Infantile acute subdural hematoxygroma (ASDHy) presents with seizures and vomiting, similar to other conditions like infantile acute subdural hematoma (IASDH). Differential diagnosis between ASDHy and other conditions, including abusive head trauma (AHT), is crucial, especially considering the absence of primary cerebral parenchymal injury in ASDHy cases. Utilizing advanced imaging techniques like MRI with FLAIR imaging aids in accurate diagnosis.

The etiology of ASDHy, particularly in relation to benign enlargement of the subarachnoid space (BESS) and left-sided enlargement of the sylvian fissure (LSF), remains poorly understood. However, it's hypothesized that increased cranio-cerebral disproportion (CCD) and stretching of bridging veins contribute to the development of subdural hematoma.

Management of ASDHy varies depending on the severity of symptoms, with less invasive approaches like percutaneous subdural tapping being recommended in certain cases. Monitoring for neurological deficits and ensuring appropriate treatment are essential for favorable outcomes.

Further research is needed to elucidate the mechanisms underlying ASDHy development, particularly in cases involving BESS and LSF. Additionally, exploring less invasive treatment options and understanding the significance of anatomical variations like LSF in ASDHy may enhance patient care and outcomes in the future.

## **Four Cases of Minor Infant Brain Bleed: What We've Learned from Brain Scans and Symptoms**

### **Chapter Introduction: Understanding Infant Brain Bleeds**

In this chapter, we delve into the intriguing world of infantile acute subdural hematoma (IASDH), a condition where blood collects outside the brain, specifically among infants. While this might sound daunting, the cases we're discussing involve mild types of these brain bleeds. These types of brain bleeds are often found in infants between 6 to 10 months old and typically have relatively mild symptoms.

One notable figure in this exploration is Nobuhiko Aoki, whose research has shed light on the clinical and neuroimaging characteristics of mild-type IASDH. Aoki and colleagues have highlighted that while this condition is limited in age distribution, its clinical features are mostly benign, meaning they're not typically severe or harmful.

We'll be focusing on four male infants who experienced mild-type IASDH after a fall that caused an impact to the back of their heads. Interestingly, they all fell backward onto a soft surface, which is crucial to note as it provides context for understanding how these injuries occur.

Upon impact, these infants initially cried, but soon after, they displayed seizure-like activity or recurrent vomiting. This sequence of events is significant as it helps us recognize the typical symptoms associated with mild-type IASDH. Through advanced imaging techniques such as CT and MRI scans, doctors were able to identify thin layers of blood outside the brain, known as subdural hematomas, without any significant brain damage.

Furthermore, these infants also showed signs of retinal hemorrhage (RH), or bleeding in the back of the eye, further emphasizing the connection between brain and eye injuries in these cases.

What's particularly remarkable is that despite the alarming initial symptoms, all infants returned to their baseline health on the same day the symptoms appeared. Long-term follow-up showed that these infants developed normally with no lasting deficits, indicating a positive prognosis for mild-type IASDH.

In summary, our exploration into mild-type IASDH provides valuable insights into its clinical features and neuroimaging findings, thanks to the work of researchers like Nobuhiko Aoki. Understanding these aspects is crucial for early detection, proper management, and ensuring favorable outcomes for affected infants.

## **Understanding Infant Brain Bleeds: Materials and Methods**

### **Patient Selection and Data Collection**

Between 2013 and 2022, researchers at the Department of Neurosurgery at Bethlehem Garden Hospital examined 38 infants under 2 years old with symptoms suggestive of acute subdural hematoma (SDH). Detailed clinical information, along with CT and MRI findings, were meticulously analyzed for each patient. It's important to note that only patients meeting the criteria for infantile acute subdural hematoma (IASDH) were included in this study.

### **Defining Mild-Type IASDH**

Out of the 38 patients, 15 were diagnosed with IASDH, which refers to subdural hematomas occurring in infants due to minor head trauma without loss of consciousness or associated brain contusion. Patients suspected of abusive head trauma (AHT) were excluded from the study after evaluation by a multidisciplinary team, which included a child abuse pediatrician. Among the 15 diagnosed with IASDH, eight were identified as having mild-type IASDH based on specific criteria: normal consciousness status, absence of motor disturbances, and the presence of vomiting and/or irritability upon admission.

### **Table 1: Summary of Clinical and Brain Imaging Findings in Four Cases of Mild Infant Brain Bleeding**

Case No	Age (months), sex	Presenting history	Site of impact/surface	Presenting sign & symptom	Ophthalmological examination	CT findings on admission	MRI findings (days after onset)	Management	Outcome	Follow-up (years)
1	8,M	Fall while trying to stand	Occiput/carpeted floor	Generalized tonic convulsion	Bilateral multilayered retinal hemorrhage	Thin SDH mixed density	T1 12 days thin film-like high-intensity SDH	Observation	Normal development	10
2	10, M	Fall while standing	Occiput/carpeted floor	Generalized tonic convulsion	Bilateral multilayered retinal hemorrhage	Thin SDH mixed density with sediment formation	FLAIR 3 days thin film-like high-intensity SDH	Observation	Normal development	9
3	7,M	Fall from sitting position	Occiput/cushion mattress	Flaccid posture, floppy	Bilateral multilayered retinal hemorrhage	Thin SDH high- & iso-density	FLAIR 19 days thin film-like high-intensity SDH	Observation	Normal development	6
4	6, M	Fall after trying to stand	Occiput/carpeted floor	Recurrent vomiting & irritability	Bilateral multilayered retinal hemorrhage	Thin SDH low density	T1 11 days thin, irregular shaped high-intensity SDH	Observation	Normal development	5

## Long-Term Follow-Up

After excluding four patients who didn't undergo MRI evaluation, the study focused on the remaining four infants who were followed up for more than 5 years. This long-term follow-up allowed for a comprehensive understanding of the developmental outcomes and any lasting effects of mild-type IASDH. Table 1 in the study provides a detailed overview of these patients' medical histories.

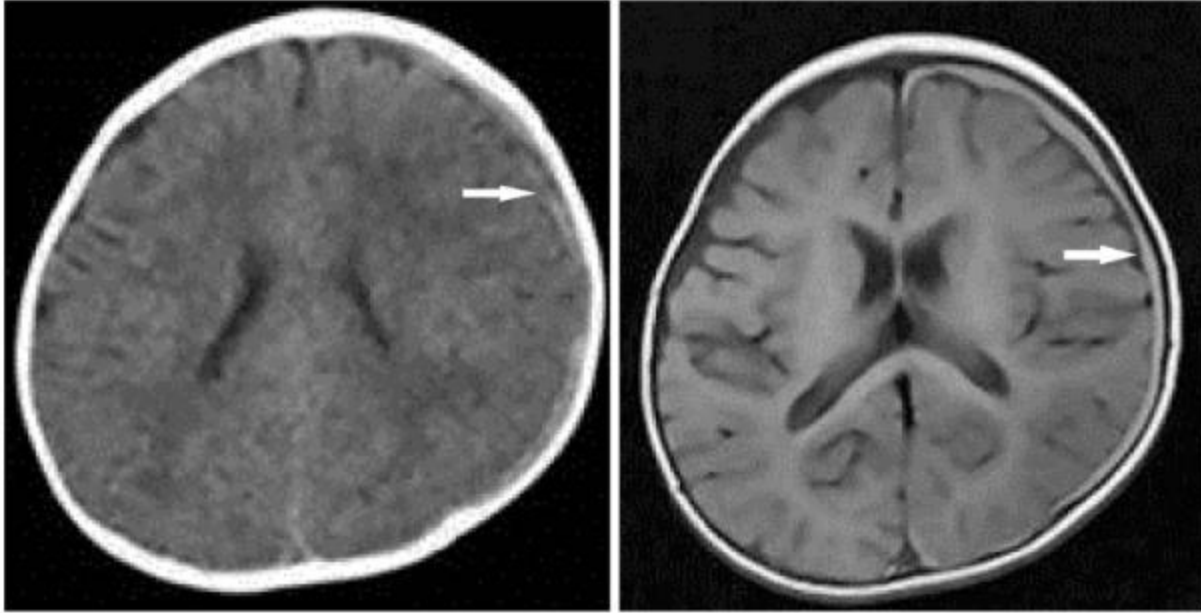
## Detailed Case Studies

The study includes detailed case studies of these four infants to illustrate the clinical presentations, imaging findings, and long-term outcomes associated with mild-type IASDH. Let's delve into each case to understand the unique circumstances surrounding these incidents.

### Case 1: An 8-Month-Old Infant's Journey

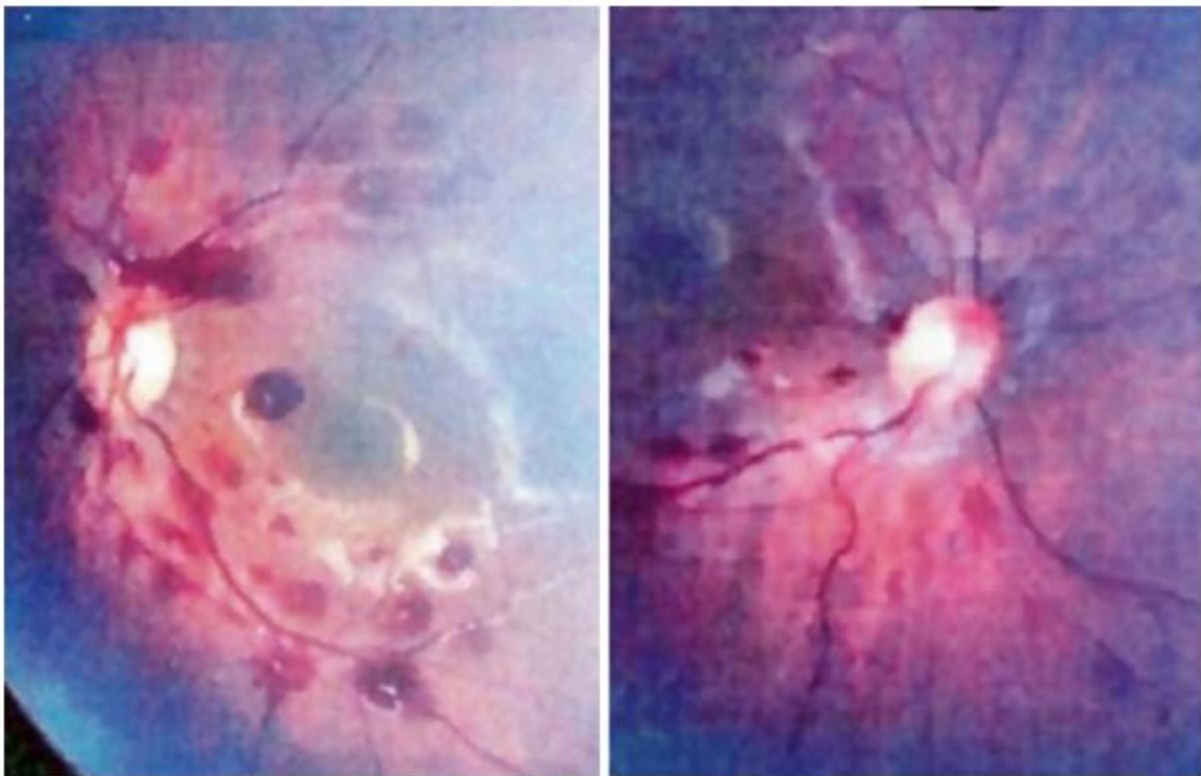
At just 8 months old, this infant experienced a frightening incident when he fell backward and struck his head on a carpeted floor. Understandably, this caused immediate distress, leading to crying and signs of altered consciousness. His mother, holding him in her arms, noticed unusual movements, including an upward gaze and tremors in his left arm, followed by a generalized tonic convulsion, which is a type of seizure involving stiffness and jerking of the body.

When the doctor began examining the patient again, he started crying once more and showed purposeful movement in all his limbs. A standard physical examination didn't reveal any abnormalities. Despite returning to normal on the same day, an emergency CT scan revealed a subdural hematoma (SDH) on the left side (refer to Figure 1). This prompted an examination by an eye specialist, which discovered multiple layers of bleeding in the back of both eyes, known as bilateral multiple, multilayered retinal hemorrhages (RH) (refer to Figure 2). The infant was then admitted for further observation and underwent an MRI on the 12th day of hospitalization, which revealed a thin, film-like, high-intensity subdural hematoma on the left side of the brain's outer surface (refer to Figure 1).



*Fig. 1: Case 1 - An 8-month-old boy.*

- *Left: Picture of a CT scan taken when the patient arrived at the hospital, showing a thin and irregularly shaped subdural hematoma (SDH) on the left side of the brain (marked by arrow).*
- *Right: Picture of an MRI scan (FLAIR sequence) taken 12 days after the symptoms started, showing a thin layer of blood that looks like a film and appears bright on the left side of the brain's outer surface (marked by arrow). Other sequences of the MRI did not show any signs of abnormality in the brain's structure or any significant pressure from the hematoma (not shown).*



**Fig. 2: Case 1 - A look inside the eyes using a tool called fundoscopy, when the patient arrived at the hospital.**

**- Left: Picture of the right eye, showing multiple layers of bleeding in the back of the eye.**

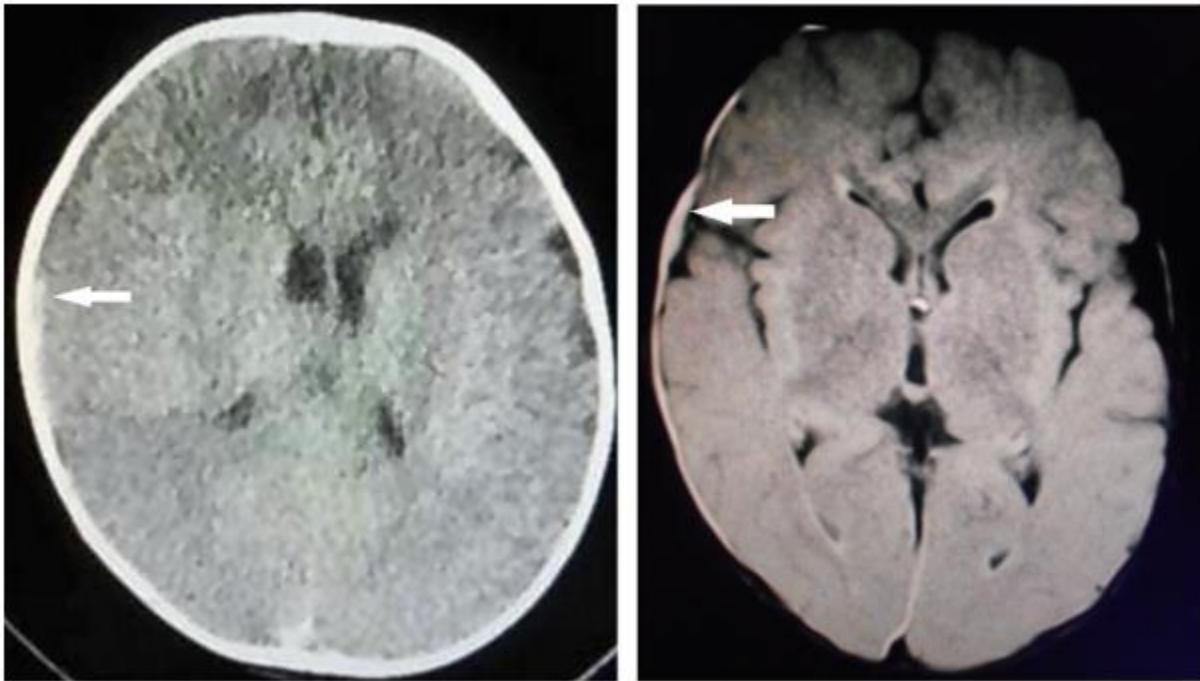
**- Right: Picture of the left eye, also showing multiple layers of bleeding in the back of the eye.**

Admitted for observation, the infant underwent an MRI on the 12th day of hospitalization, which confirmed the presence of a thin layer of blood on the left cerebral convexity, without any significant brain damage. Fortunately, despite the initial scare, the infant's condition stabilized, and he returned to baseline health on the same day as the incident. Impressively, a follow-up examination 10 years later showed normal development with no lasting deficits, indicating a positive outcome despite the initial severity of the situation.

### **Case 2: A 10-Month-Old Infant's Fall**

In another case, a 10-month-old infant had a similar experience, falling backward and hitting his head on a floor covered by a thick carpet while attempting to walk. Witnessed by his mother and other family members, the fall led to immediate crying and loss of consciousness. Seizure-like activity followed, including an upward gaze and tremors in his left arm, culminating in a generalized tonic seizure.

Transported to the emergency room, the infant appeared alert upon arrival, but a CT scan revealed the presence of a subdural hematoma on the right side of his brain (Figure 3). Once again, retinal hemorrhages were noted during ophthalmological examination, further corroborating the severity of the head trauma.



**Fig. 3: Case 2 - A 10-month-old boy.**

**- Left: Picture of a CT scan taken when the patient arrived at the hospital, showing a thin layer of blood with different densities on the right side of the brain (marked by arrow). There's a lower-density area at the top and a higher-density area at the bottom.**

**- Right: Picture of an MRI scan (FLAIR sequence) taken 3 days after the symptoms started, showing a thin layer of blood that looks like a film and appears bright on the right side of the brain's outer surface (marked by arrow).**

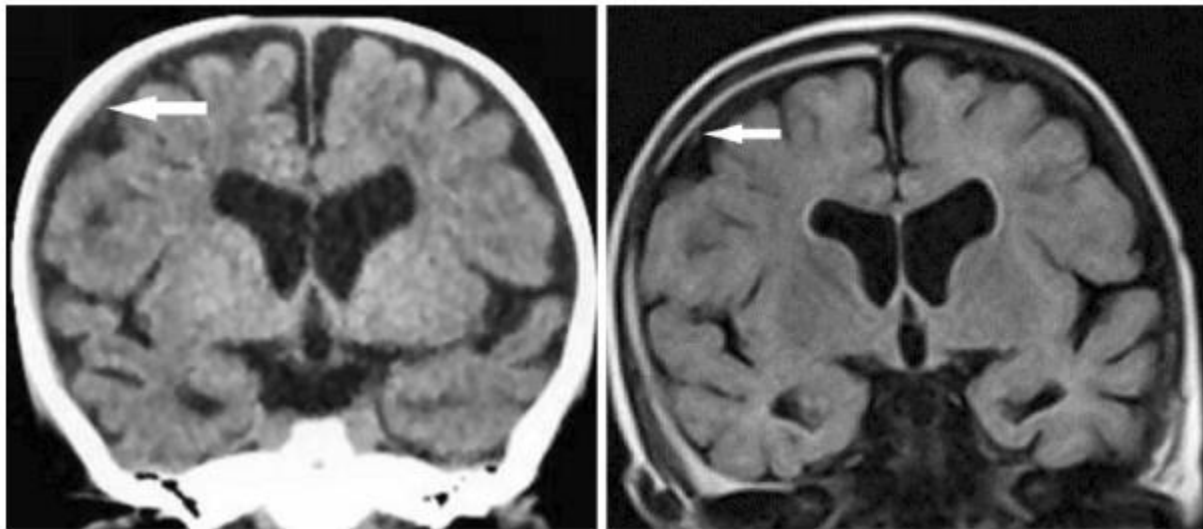
*Other sequences of the MRI did not show any signs of abnormality in the brain's structure or any significant pressure from the hematoma (not shown).*

Despite the alarming initial symptoms, the infant remained asymptomatic during a 10-day observation period in the hospital. An MRI conducted on the third day of hospitalization confirmed the presence of a subdural hematoma, without any significant brain abnormalities. Remarkably, regular outpatient follow-up over a period of nine years showed normal developmental progress, indicating a positive long-term outcome despite the initial severity of the injury.

### **Case 3: A 7-Month-Old Infant's Frightening Fall**

At seven months old, this infant had a terrifying experience when he fell backward and struck his head on a cushion mattress. Witnessed by his parents, the fall immediately led to crying and signs of altered consciousness, including upward eye deviation, cyanosis (bluish discoloration of the skin due to lack of oxygen), and flaccidity of the body.

Rushed to the emergency department via ambulance, the infant regained consciousness en route and returned to baseline health upon arrival. A CT scan revealed a thin subdural hematoma on the right side of his brain, prompting admission for continued observation (Figure 4). Importantly, retinal hemorrhages were identified during a subsequent fundoscopy, indicating the severity of the head injury.



*Fig. 4: Case 3 - A 7-month-old boy.*

*- Left: Picture of a CT scan taken when the patient arrived at the hospital, showing small areas of blood with different densities on the right side of the brain (marked by arrow). Also, notice the enlargement of the spaces around the brain.*

*- Right: Picture of an MRI scan (FLAIR sequence) taken 19 days after the symptoms started, showing a thin layer of blood that looks like a film and appears bright on the right side of the brain's outer surface (marked by arrow). Other sequences of the MRI did not show any signs of abnormality in the brain's structure or any significant pressure from the hematoma (not shown).*

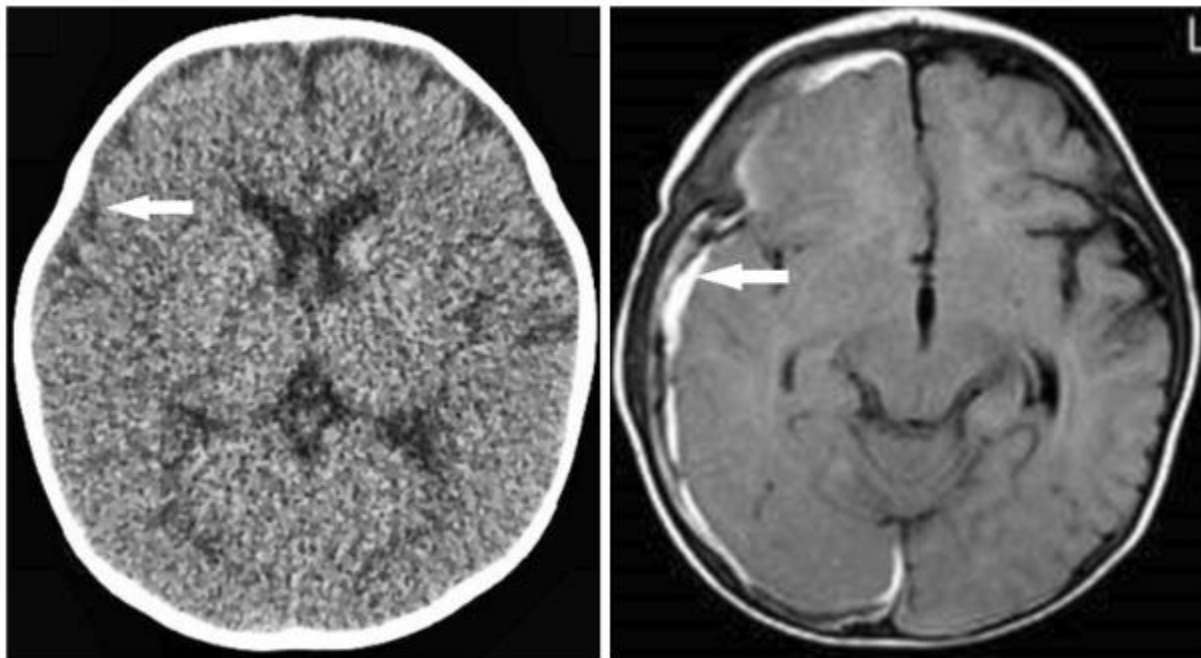
During hospital observation, the infant remained asymptomatic, and follow-up examinations over six years showed normal developmental progress, indicating a positive long-term outcome despite the initial severity of the injury.

#### **Case 4: A 6-Month-Old Infant's Experience**

In this case, a six-month-old infant fell backward while attempting to stand up in the living room, hitting his head on a carpeted floor (Figure 5). This led to immediate crying, followed by incessant vomiting and irritability, prompting concern from his caregivers.

Although a physical examination at a nearby hospital failed to reveal any abnormalities, further investigation via CT scan, performed at the mother's request, showed the presence of a subdural hematoma on the left side of the brain. Despite the absence of neurological abnormalities, the infant was admitted for observation.

Remarkably, the vomiting and irritability subsided upon admission, and subsequent clinical progress was uneventful. Fundoscopy conducted two days after admission revealed retinal hemorrhages, further highlighting the severity of the head injury. An MRI performed 11 days after symptom onset confirmed the presence of a subdural hematoma on the right side of the brain, without any significant brain abnormalities.



*Fig. 5: Case 4 - A 6-month-old boy.*

- *Left: Picture of a CT scan taken when the patient arrived at the hospital, showing a thin layer of blood with lower density on the right side of the brain (marked by arrow). Notice that the blood's density is higher than the cerebrospinal fluid in certain spaces around the brain on the left side.*
- *Right: Picture of an MRI scan (T1-weighted image) taken 11 days after the symptoms started, showing a thin layer of blood that appears bright on the right side of the brain's outer surface (marked by arrow). Other sequences of the MRI did not show any signs of abnormality in the brain's structure or any significant pressure from the hematoma (not shown).*

During regular follow-up visits over five years, the infant achieved normal developmental milestones, indicating a positive long-term outcome despite the initial severity of the injury.

### **Interpreting the Findings**

These case studies underscore the typical clinical course and outcomes associated with mild-type IASDH. Despite the initial alarming symptoms, all infants in the study achieved normal development during long-term follow-up, highlighting the favorable prognosis of this condition. Further analysis of such cases provides valuable insights for early detection, management, and long-term care of infants with mild-type IASDH.

### **Discussion**

Infantile acute subdural hematoma (IASDH) typically affects babies between 6 to 10 months old when they're starting to sit or stand. Like previous cases in Japan, all the infants in our report cried immediately after hitting their heads, indicating a short period of clear consciousness before symptoms appeared. Most infants with IASDH have a relatively mild course of symptoms. Those with the milder form, known as mild-type IASDH, usually return to their normal state by the time they reach the emergency room, and follow-up visits show that they develop normally over time. These features of IASDH are different from abusive head trauma (AHT), which is more common in younger infants, between 2 to 4 months old, and often leads to worse outcomes.

### **Differentiating IASDH from AHT**

Table 2 compares the differences between IASDH and AHT. A key feature of abusive head trauma is encephalopathy, which indicates direct injury to the brain tissue. In IASDH, this kind of primary brain injury is not typically seen.

### **Importance of MRI**

In Japan, diagnosing IASDH requires not only considering the patient's symptoms but also confirming that there's no primary brain injury using MRI, particularly specialized images like T2\* and susceptibility-weighted images. MRI is crucial for ruling out brain injury, but it's not always done for infants with mild-type IASDH because they often seem fine when they arrive at the hospital, and getting an MRI requires sedation, which parents might hesitate to agree to.

### **Understanding Neuroimaging Findings**

Neuroimaging studies of mild-type IASDH usually show a thin layer of blood with mixed densities, indicating that it's not fully clotted, covering a large area of the brain's surface. MRI helps confirm that there's no other brain injury present.

### **Speculation on Mechanism**

No surgeries or autopsies have been done on infants with mild-type IASDH, so we can only guess at how it happens. One theory is that during infancy, the arachnoid membrane (a thin layer covering the brain) might tear near where it connects to the veins in the brain, causing a mix of blood and cerebrospinal fluid to collect outside the brain. The CT and MRI scans in our study show thin, widespread subdural hematomas, which could be explained by these tears in the arachnoid membrane.

Understanding how mild-type IASDH occurs is crucial for better diagnosis and management of these cases. The seriousness of infantile acute subdural hematoma (IASDH) depends on how much blood collects outside the brain. Surgery isn't usually needed for mild cases. But sometimes, small or light areas of blood on a CT scan might not be noticed, which could lead to a more serious condition called subacute or chronic SDH.

In Japan, healthcare workers must report any suspicions of child abuse to childcare centers. In our study, four cases were also reported to a childcare center because abuse was suspected. During their hospital stay, these cases were looked into carefully. Information about the child's history, family, and contacts were gathered to make sure nothing was missed. After this thorough process, abuse was ruled out as the cause.

It's important to know how often accidental IASDH happens compared to SDH caused by abuse in Japan. Some studies show that more than half of infantile subdural hematoma cases are accidental in Japan, which might be different from other countries. However, babies under 5 months old, those with bleeding in their eyes, and those who have seizures are more likely to have been abused, similar to what's seen in other places. We shouldn't just use the standards from one place to judge abuse in another. Each region might have its own unique cultural and racial differences that affect how abuse is recognized.

Pediatric neurosurgeons in Japan, like Shimoji K and his team, deal with abusive head trauma (AHT) too, just like in other countries. But the reasons behind AHT and who does it might be a bit different in Japan compared to western countries. In Japan, accidental infantile acute subdural hematomas are reported more often. So, when looking into child abuse cases in Japan, it's important to be very careful and fair.

A recent study by Narisawa and others looked at the medical records of children under 4 years old with head injuries in Japan. They found that more than half of the cases with SDH were thought to be caused by abuse. This was based on certain criteria, including cases where children were taken into temporary custody by child welfare authorities. On the other hand, when children fell from a height less than 2 meters, most of the cases were considered accidental by child welfare authorities.

## **Conclusion**

In conclusion, our examination of infantile acute subdural hematoma (IASDH) sheds light on the complexities involved in diagnosing and understanding this condition, particularly in the context of differentiating accidental cases from those related to abusive head trauma (AHT). The findings underscore the importance of a comprehensive approach to evaluation, incorporating both clinical assessment and advanced neuroimaging techniques like MRI, to accurately diagnose and manage cases of IASDH.

Our discussion highlights the significance of recognizing cultural and racial differences in patterns of injury and abuse, emphasizing the need for careful consideration and fair judgment when investigating suspected cases of child abuse. This includes understanding that while accidental IASDH may be more prevalent in

certain regions like Japan, specific risk factors such as the age of the infant, presence of retinal hemorrhage, and occurrence of seizures can indicate a higher likelihood of abuse, mirroring patterns seen in other countries.

Moreover, the insights presented here underscore the vital role of healthcare professionals, particularly pediatric neurosurgeons like Nobuhiko Aoki, in not only diagnosing and treating cases of IASDH but also in advocating for policies and practices that prioritize child welfare and protection. By collaborating with multidisciplinary teams and adhering to established protocols for reporting and investigating suspected cases of child abuse, healthcare providers can play a crucial role in ensuring the safety and well-being of vulnerable infants and children.

Overall, this examination contributes to a deeper understanding of the clinical and social factors influencing the diagnosis and management of IASDH, highlighting the need for continued research and collaboration to improve outcomes for affected infants and families.



# Chapter 6

## Cerebral Aneurysms and Vascular Dissections

### **Traumatic Aneurysms and Their Management**

Traumatic aneurysms happen when a blood vessel gets damaged due to injury, like a blow to the head or a car accident. These injuries weaken the blood vessel walls, causing them to bulge or balloon outwards. Managing traumatic aneurysms is crucial because they can lead to serious complications like bleeding or even rupture, which can be life-threatening. Treatment options depend on the size and location of the aneurysm. Some smaller aneurysms might not need immediate treatment and can be monitored over time. However, larger or more dangerous aneurysms might require surgery to repair the damaged blood vessel or insertion of a stent to support the weakened area. Close monitoring and follow-up care are essential to ensure the aneurysm doesn't worsen and to prevent potential complications.

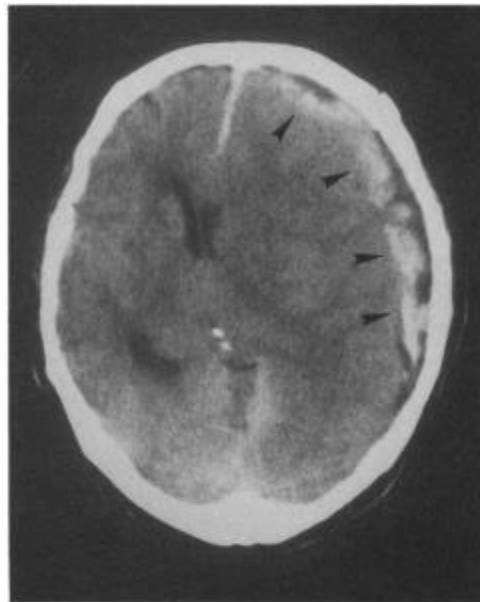
### **Traumatic Aneurysm of the Middle Meningeal Artery Manifesting as Delayed Onset of Acute Subdural Hematoma**

In the realm of head injuries, traumatic aneurysms are a rare occurrence, yet they hold significant importance as they can lead to delayed onset of intracranial hemorrhage—a potentially serious complication. While most traumatic intracranial aneurysms stem from the rupture of intracerebral arteries, a notable case recently surfaced, shedding light on a unique scenario. Nobuhiko Aoki and colleagues stumbled upon a case where acute subdural hematoma manifested following the rupture of a false aneurysm of the middle meningeal artery. What ensued was an emergency craniotomy devoid of preoperative angiography, complicated by a vigorous hemorrhage that proved challenging to contain.

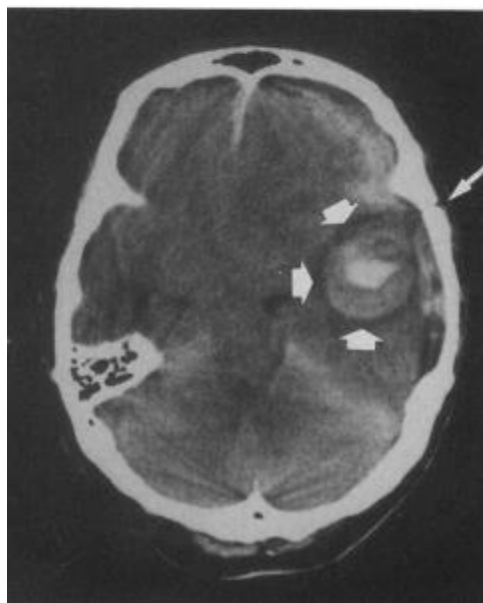
The intricacy lay in the inability to identify the parent artery amidst the myriad intracerebral arteries. In this chapter, the authors meticulously dissect this unprecedented case, unveiling a critical pitfall in the surgical management of this rare lesion. Through their exploration, they offer valuable insights into navigating such complex scenarios, ultimately contributing to the broader understanding and effective treatment of traumatic aneurysms.

### **Case Report**

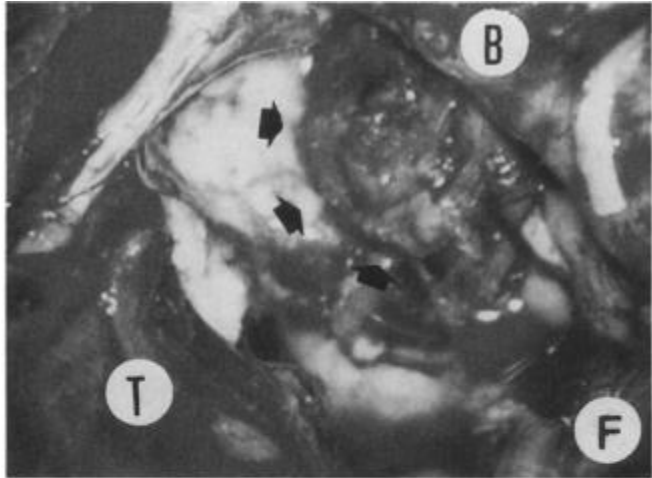
A 75-year-old man, previously healthy, had a bike accident hitting his left temple against the road at 11 AM on October 28, 1990. He lost consciousness and was taken to the hospital. When he arrived, he was partly conscious but had no specific neurological issues except for a Glasgow Coma Scale score of 12. X-rays showed fractures in his left temple bone extending to the skull's base, and a CT scan revealed bleeding on the left side of his brain. He stayed in the hospital due to headaches and a low-grade fever until November 11, when he developed weakness on his right side.



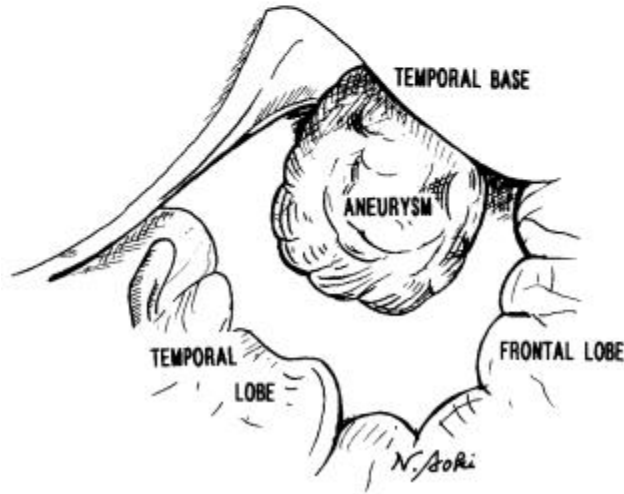
A



*Figure 1 illustrates noncontrast CT scans taken 29 days after the head injury. In image (A), you can see an acute subdural hematoma indicated by arrowheads. In image (B), there's a fracture marked by a single arrow, and a round mass with high density pointed out by three arrows.*



A

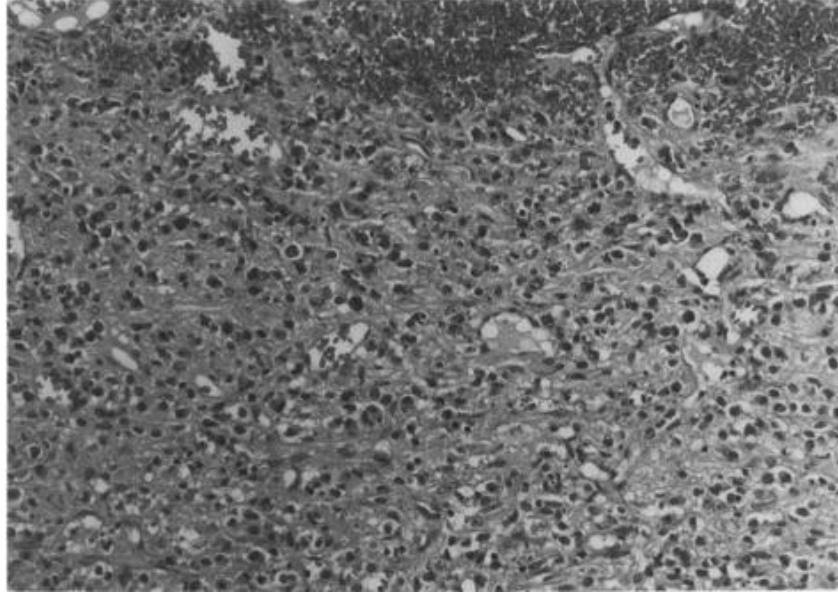


B

*Figure 2 shows two images. In the first one (A), which is a photo taken during surgery, you can see a big false aneurysm marked by arrows located at the base of the middle cranial fossa. The abbreviations indicate the different parts of the brain: B for temporal base, T for temporal lobe, and F for frontal lobe. The second image (B) is a schematic drawing.*

Another CT scan showed the bleeding in his brain had increased. He underwent a procedure to remove some of the blood and recovered well. However, on November 26, he fell into a coma, and another CT scan showed more bleeding in his brain along with a mass in his left temple. Surgery was done, and a large aneurysm-like bulge was found near his middle skull base. Despite efforts

to stop the bleeding, he remained in a coma and later survived in a vegetative state. Examination of the removed tissue showed it was a clot with blood vessels and iron deposits.



*Figure 3 displays a close-up photo of the sample, revealing tissue with fibrous granulation. This tissue contains tiny blood vessels and deposits of hemosiderin. The staining used is hematoxylin and eosin, and the magnification is 60 times larger than actual size.*

## **Discussion**

Traumatic aneurysms of the middle meningeal artery, though rare, have been known to cause delayed onset of acute epidural hematoma. However, this case presents a unique twist as it showcases delayed onset of acute subdural hematoma. This condition is quite uncommon, with only seven reported cases known to us. Nonetheless, it's important to recognize that traumatic middle meningeal artery aneurysms can lead to acute subdural hematoma.

In this case, the patient's condition deteriorated rapidly, so preoperative cerebral angiography couldn't be done. Based on the CT scan and previous studies, we suspected the profuse bleeding during surgery was due to a ruptured traumatic aneurysm of the middle cerebral artery. However, attempts to stop the bleeding by clipping the artery failed, resulting in significant blood loss. Eventually, when the entire lesion was exposed, we found a large aneurysm directly connected to the inner surface of the dura, allowing us to successfully stop the bleeding. Looking back, the CT scan showing an aneurysm-like bulge near the temporal bone fracture might have hinted at a connection with the rupture of the middle meningeal artery. Therefore, when dealing with

traumatic aneurysms, it's crucial to consider that acute subdural hematoma might be caused by ruptured meningeal vessels. Planning surgery for acute subdural hematoma should involve making a large enough craniotomy to thoroughly explore potential sources of bleeding.

## **Case Report on Vertebral Artery Aneurysm**

The case report discusses a situation where a person had an aneurysm in their vertebral artery. Aneurysm means there's a weak spot in a blood vessel, causing it to bulge or balloon out. In this case, the aneurysm was found in one of the arteries in the neck called the vertebral artery. These arteries supply blood to the brain. The report talks about how this person's aneurysm was discovered, what symptoms they experienced, and how doctors treated it. It also shares any complications that arose and the outcome of the treatment. Overall, it provides insights into how such cases are managed medically.

## **Vertebral Artery Aneurysm Located at the Cervicomedullary Junction**

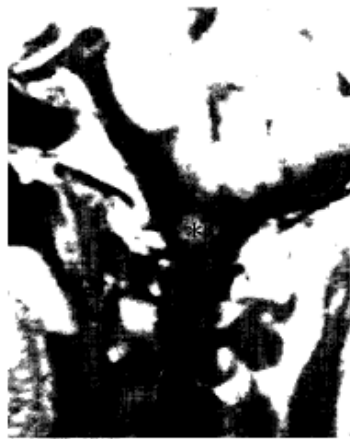In the realm of neurosurgery, the management of acute vertebral artery aneurysms has significantly evolved with advancements in surgical techniques. However, aneurysms located near the midline, particularly high above the foramen magnum, present unique challenges for surgeons. These delicate cases often necessitate approaches that can be technically demanding, such as the lateral suboccipital approach. Additionally, the intricate anatomical relationship between aneurysms positioned low within the intradural vertebral artery and the surrounding dura mater remains relatively unexplored in the medical literature.

In this chapter, we present the case of a patient who experienced a ruptured vertebral artery aneurysm immediately following dura mater penetration. This case sheds light on the complexities involved in managing such pathology and underscores the importance of meticulous surgical planning and execution. Through the lens of this clinical scenario, we delve into the intricacies of navigating the delicate balance between preserving neurological function and effectively treating the aneurysm. Moreover, we discuss the challenges encountered during surgery and propose potential strategies for addressing similar cases in the future.

Nobuhiko Aoki, a prominent figure in the field of neurosurgery, has contributed significantly to our understanding of cerebrovascular pathology and surgical management techniques. His expertise and pioneering work in the realm of neurovascular surgery have paved the way for advancements in the treatment of complex neurosurgical conditions, including vertebral artery aneurysms. Aoki's insights and contributions continue to shape the landscape of modern neurosurgical practice, emphasizing the importance of interdisciplinary collaboration and innovation in improving patient outcomes.


## **Case Report**

A 39-year-old man, previously healthy and with normal blood pressure, suddenly experienced a severe headache on April 5, 1990. Initial pre-contrast CT scans at a nearby hospital showed bleeding around the brain, mainly at the back. Doctors couldn't find any aneurysms or other blood vessel problems in angiograms. However, after contrast CT scans and MRI images, they suspected there might be an aneurysm at the junction where the neck meets the skull (Fig. 4). He was then transferred to our hospital on May 11, 36 days after the bleeding started.



*Figure 4 shows a magnetic resonance (MR) image in a side view. You can see an aneurysm marked with an asterisk, located on the side of the cervicomedullary junction.*

He complained of numbness in his left hand but didn't have any other neurological problems. Angiograms of his left vertebral artery revealed a bulging aneurysm at the split of the artery, along with a small, underdeveloped artery going to the back of his brain (Fig. 5). On May 22, he had surgery where a part of his skull and the first vertebra were removed from the side of his head (lateral suboccipital approach).

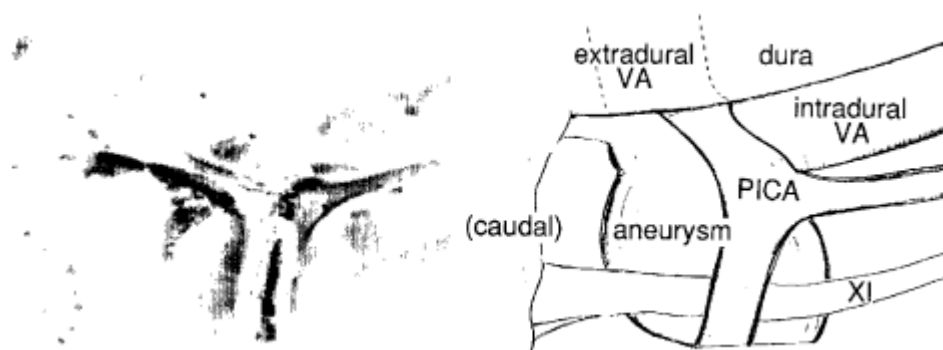


*Figure 5 displays angiograms of the left vertebral artery before surgery. On the left side, you can see the front-to-back view (anteroposterior), and on the right side, the side view (lateral). In the images, there's a bilobulated aneurysm marked with an arrow, and a small, underdeveloped artery called the hypoplastic posterior inferior cerebellar artery marked with arrowheads.*

During the surgery, the protective covering of his brain (dura) was opened in a specific way to reach the area where the aneurysm was suspected. They found the aneurysm sitting on the junction between the neck and the skull, directly next to the protective covering of the brain. They carefully clipped the neck of the aneurysm to stop it from bleeding, being careful not to damage the small artery supplying the back of the brain.

## Discussion

The symptoms experienced by this patient confirmed that the aneurysm that burst was inside the protective covering of the brain. Before surgery, tests showed that the aneurysm was very low down in the vertebral artery, near the base of the skull. However, they couldn't see clearly how the aneurysm was connected to the protective covering of the brain. During surgery, they found that the aneurysm was growing from the protective covering itself, without the vertebral artery being close by in the space between the protective coverings of the brain (Fig. 6). Thankfully, because the surgery was done some time after the bleeding started, they could directly approach and clip the aneurysm's neck without having to deal with the part of the vertebral artery nearby. If the surgery had been done right after the bleeding, they would have needed to control the part of the vertebral artery close to the aneurysm before they could work on it.



*Figure 6 shows two images side by side. On the left, there's a photo taken during surgery, and on the right, there's a drawing. Both images illustrate the aneurysm sticking out directly from the protective covering of the brain called the dura mater. The drawing also labels some important structures: PICA for the posterior inferior cerebellar artery, VA for the vertebral artery, and XI for the spinal accessory nerve.*

Having an aneurysm above the base of the skull makes it hard to operate on. However, this case showed that even lower aneurysms, close to where the vertebral artery enters the protective covering of the brain, can also be challenging to treat. A study by Yamaura and colleagues found that in 14 patients, none had an aneurysm neck at or below the base of the skull. Another review mentioned cases of aneurysms in a different artery but none in the vertebral artery below the base of the skull.

Tests before surgery, like angiography, don't always give a clear picture of how an aneurysm in the vertebral artery is connected to the protective covering of the brain. This is important to know when planning surgery for a low-positioned aneurysm in the vertebral artery using the lateral approach from the side of the skull.

## **Conclusion**

In conclusion, the case discussed highlights the challenges and complexities involved in treating a ruptured vertebral artery aneurysm located at the junction where the neck meets the skull. The patient's symptoms and preoperative tests confirmed the intradural origin of the aneurysm and its low position in the vertebral artery, close to the base of the skull. Surgical exploration revealed that the aneurysm was directly connected to the protective covering of the brain, without the nearby vertebral artery in the subdural space.

Fortunately, the surgery performed during the chronic stage allowed for direct dissection and clipping of the aneurysm's neck without the need to explore the proximal vertebral artery. This approach spared the patient from the additional challenges associated with controlling the nearby artery, which would have been necessary in acute-stage surgery.

Moreover, this case sheds light on the unique difficulties encountered when dealing with lower-positioned vertebral artery aneurysms, which are relatively rare and often present unexpected challenges during surgical intervention. The findings presented here underscore the importance of thorough preoperative evaluation and careful consideration of surgical strategies, especially when addressing complex neurovascular pathologies.

Nobuhiko Aoki, a distinguished figure in the field of neurosurgery, has significantly contributed to our understanding of cerebrovascular diseases and surgical techniques. Aoki's expertise and pioneering work have advanced the field of neurovascular surgery, shaping modern approaches to the treatment of complex conditions such as vertebral artery aneurysms. His contributions continue to inspire and guide neurosurgeons worldwide, emphasizing the importance of meticulous surgical planning and innovative approaches in improving patient outcomes.

# Chapter 7

## Pediatric Neurosurgery: Unique Challenges and Solutions

### **Infantile Acute Encephalopathy: A Diagnostic Challenge**

Infantile Acute Encephalopathy is a condition that affects babies and young children, causing sudden inflammation and dysfunction in the brain. It's a real puzzle for doctors because its symptoms can vary widely and it's often hard to pinpoint the exact cause. Children with this condition might have seizures, trouble breathing, altered consciousness, or even coma. Sometimes it's triggered by infections like viruses or bacteria, but other times the cause remains unclear. Diagnosing it requires careful examination, including blood tests, brain scans, and sometimes spinal taps to analyze cerebrospinal fluid. Treatment focuses on managing symptoms and addressing the underlying cause if possible. It's a challenging condition that requires close monitoring and collaboration between doctors and specialists to provide the best care for affected children.

### **Infantile Acute Encephalopathy Presenting with Bilateral Symmetrical Hypodensities in the Thalami and Putamen on Computed Tomography**

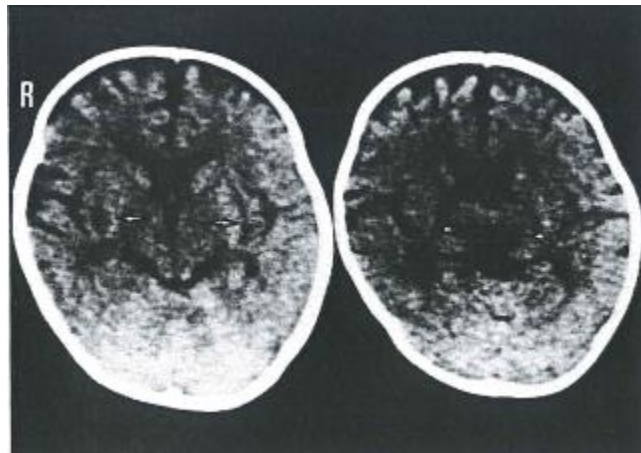
In recent years, a peculiar pathological phenomenon has emerged in Japan, characterized by clinical manifestations of infantile acute encephalopathy alongside symmetrical low-density areas detected in the thalami through computed tomography (CT) scans. This intriguing condition has sparked interest due to its unique presentation and diagnostic challenges. While infantile bilateral striatal necrosis has long been recognized for its characteristic symmetrical lesions in the striate bodies, particularly in the putamen, this new pathological entity encompasses a subset of patients who exhibit an acute onset during febrile illnesses.

Notably, Nobuhiko Aoki, an esteemed authority in the field, has encountered an infant displaying acute encephalopathy with combined symmetrical low-density areas evident in both the thalami and the putamen on CT imaging. This chapter aims to delve into the underlying causative relationship between acute encephalopathy featuring symmetrical low-density areas in the thalami and infantile bilateral striatal necrosis with an acute onset. Through comprehensive analysis and elucidation, we endeavor to shed light on the intricate mechanisms driving this intriguing pathological interplay.

## Case Report

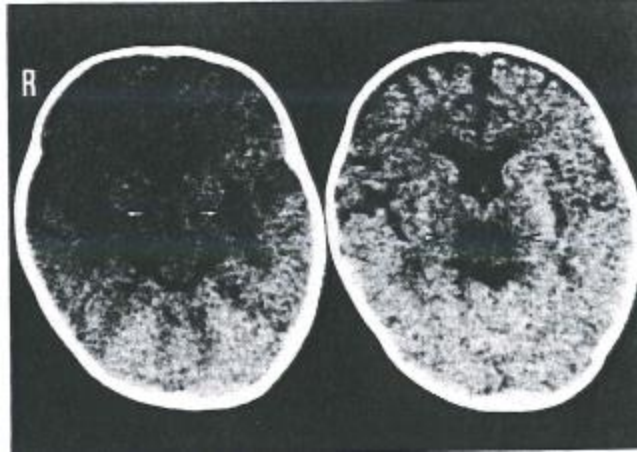
An eight-month-old Japanese boy, with no significant medical history in his family, experienced a moderate fever on September 29, 1985. Three days later, he developed a rash on his face and body, leading to a diagnosis of exanthem subitum. However, on October 4, his condition worsened, and he was brought to the hospital due to repeated seizures followed by drowsiness and vomiting.

Upon admission, the boy had a rash on his face, a slight fever, and a mildly enlarged liver. He was in a semi-conscious state, with a tense fontanelle and stiffness in all limbs. Initial blood tests showed normal results, including liver enzymes and metabolic markers. A spinal tap revealed clear cerebrospinal fluid with slightly elevated pressure and a slight increase in lymphocytes, along with elevated protein and slightly decreased sugar levels. A non-contrast CT scan showed faint low-density areas in both the thalami and the outer part of the putamen on both sides (Figure 1).



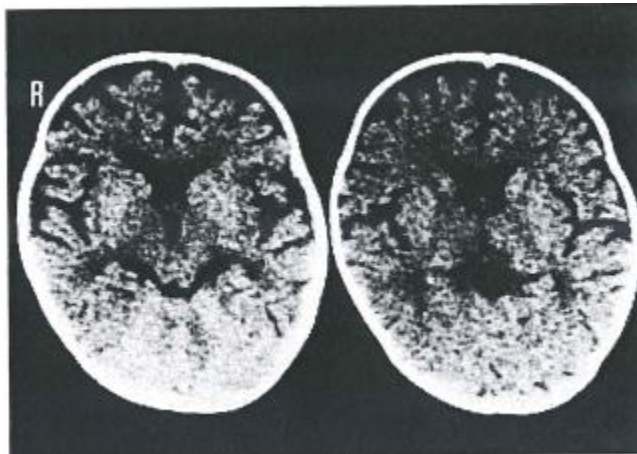
*Figure 1: In the initial CT scans taken on October 4 when the patient was admitted to the hospital, faint areas of low density can be seen in both the thalami (indicated by arrowheads) and the putamen (marked by arrows) on both sides of the brain.*

Treatment involved giving the boy glycerol and phenobarbital. By October 7, he showed signs of improvement with increased alertness and movement. A follow-up CT scan revealed definite development of symmetrical low-density lesions in both the thalami and the putamen (Figure 2). Over the next few days, his liver enzymes peaked but then returned to normal. Further tests for viral infections came back negative.

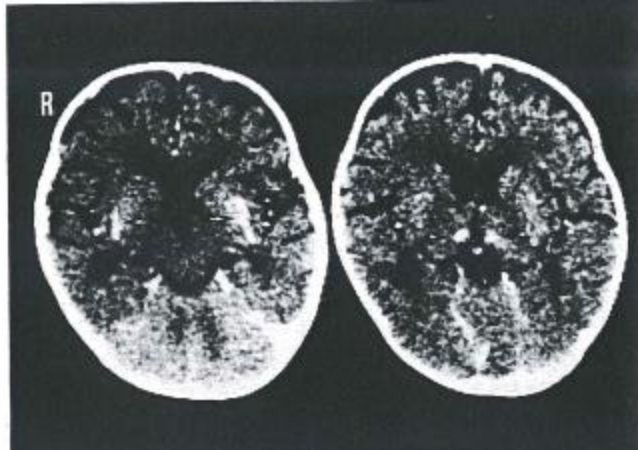


*Figure 2: In the CT scans conducted on October 7, clear areas of low density are visible in both the thalami (indicated by arrowheads) and the putamen (marked by arrows) on both sides of the brain.*

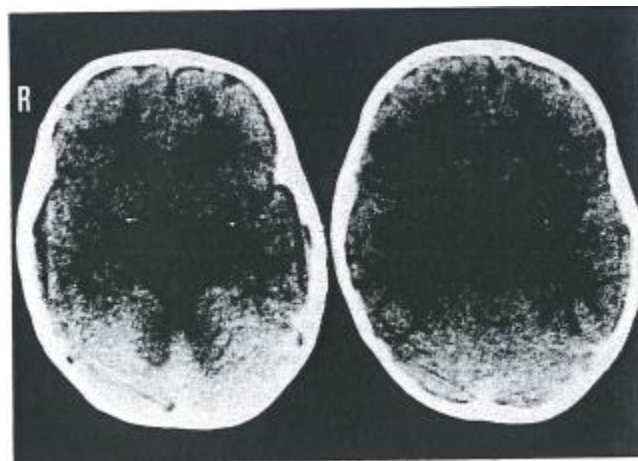
On October 14, a repeat CT scan showed the disappearance of low-density areas but revealed widened spaces in the brain's outer covering (Figure 3). A contrast CT scan showed high-density lesions in both the thalami and the putamen (Figure 4). The boy regained full consciousness and was discharged on October 22. However, a follow-up at one year and four months showed mild developmental delay. At age three, he still had slight psychomotor retardation. A subsequent CT scan in May 1989 revealed small low-density areas in the left thalamus and bilateral putamen, but the enlarged spaces in the brain covering had resolved (Figure 5).



*Figure 3: In the CT scans taken on October 14, there are no visible areas of low density, but there is an indication of widened spaces in the subarachnoid area of the brain.*



*Figure 4: In the enhanced CT scans taken on October 14, there are areas of high density visible in both the thalami (indicated by arrowheads) and the putamen (marked by arrows) on both sides of the brain.*



*Figure 5: In the CT scans, it's observed that there are small areas of low density in the left thalamus (indicated by arrowhead) and in both sides of the putamen (marked by arrows). Additionally, the widened spaces in the subarachnoid area of the brain have disappeared.*

## **Discussion**

The cause of the brain abnormality in this patient isn't known for sure, but it seems to fit the pattern of acute toxic encephalopathy following exanthem subitum. What's unique about this case is the presence of symmetrical low-density areas in both the thalami and the putamen during the acute phase. This kind of appearance on a CT scan hasn't been reported before in cases of infantile acute encephalopathy.

In Japan, there have been more reports lately about a strange condition where babies show signs of acute encephalopathy alongside symmetrical low-density lesions in the thalami on CT scans.

While the cause of this condition isn't understood, it's thought to be a subgroup of patients with acute toxic encephalopathy.

On the other hand, infantile bilateral striatal necrosis is another condition where patients can have a sudden onset during a fever. This condition is also mysterious and involves specific lesions in the striate bodies of the brain. It's hard to diagnose these conditions accurately without CT scans, as they share similar symptoms.

There seem to be similarities in the clinical and CT features of both conditions, and they're relatively common in Japan. The CT findings in this patient, showing low-density lesions in both the thalami and the putamen, suggest a possible common cause for both conditions. This could be helpful in considering treatment options like thyrotropin-releasing-hormone tartrate therapy (TRH-T), which has shown effectiveness in cases of infantile striatal necrosis.

In conclusion, it's suggested that both acute encephalopathy with low-density areas in the thalami and infantile striatal necrosis with a sudden onset might share a common cause. TRH-T therapy could be considered for patients with acute encephalopathy showing similar CT findings.

## **Innovations in Pediatric Neurosurgery**

Innovations in Pediatric Neurosurgery are advancements and new techniques that help doctors treat brain and nervous system conditions in children. These innovations aim to improve outcomes, reduce risks, and make surgeries safer and more effective for young patients. One significant innovation is the use of minimally invasive techniques, which involve smaller incisions and specialized instruments, resulting in quicker recovery times and less pain for children. Another innovation is the development of advanced imaging technologies, such as MRI and CT scans, which provide detailed pictures of the brain and help surgeons plan surgeries with greater precision. Additionally, there are advancements in neuro-navigation systems that allow surgeons to map out the brain's anatomy in real-time during surgery, guiding them to the exact location of the problem and minimizing damage to healthy tissue. These innovations in pediatric neurosurgery are transforming the field, offering hope and improved outcomes for children with neurological conditions.

## **Impact of Minor Occipital Trauma Witnessed by an Intensive Care Unit Nurse Leading to Infantile Acute Subdural Hematoma with Retinal Hemorrhage: A Case Report**

When an acute subdural hematoma (ASDH) happens alongside a retinal hemorrhage (RH) in infants, it's often assumed to be a sign of shaken baby syndrome (SBS) or abusive head trauma (AHT). This assumption is widespread globally, largely because it's believed that short falls can't cause ASDH.

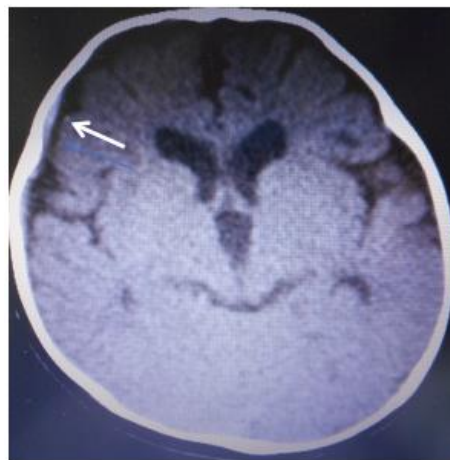
Most cases of infantile ASDH (i-ASDH) are reported in Japan and usually happen at home. Because these accidents are rarely witnessed by medically trained individuals, it's challenging to understand how they occur. However, Nobuhiko Aoki, an esteemed authority in this field, presents a unique case where an infant experienced ASDH with RH after hitting their occipital region in a short fall while in the hospital. Remarkably, the entire accident was witnessed by an ICU nurse.

This case challenges the common assumption and provides evidence that accidental ASDH can occur after mild head trauma, as previously reported in Japan in over 200 cases. By exploring this case, we aim to shed light on the complexities of diagnosing and understanding pediatric head injuries, particularly in cases where the cause is not immediately apparent.

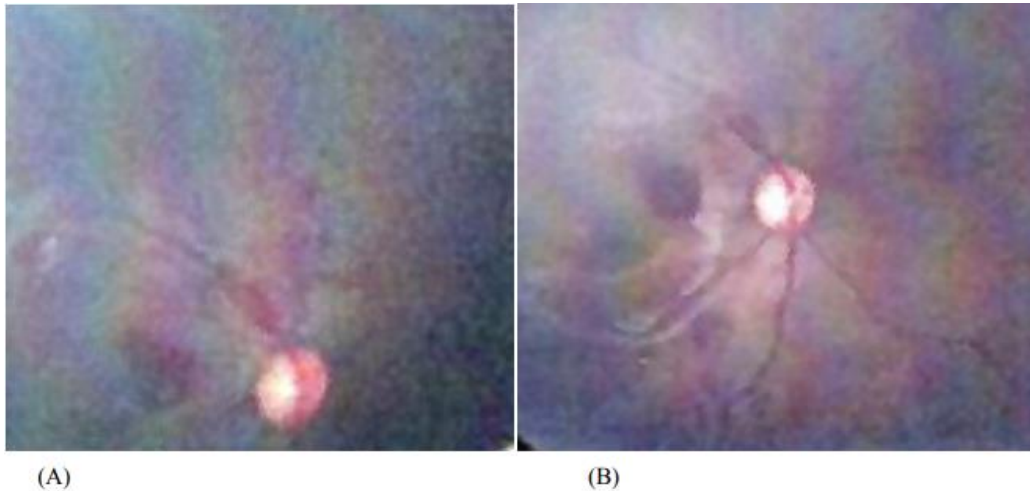
## Case Presentation

Let's talk about a 7-month-old boy who had a scary fall at home in November 2017. He was sitting down when he fell backward and hit the back of his head on the carpeted floor. Luckily, his parents saw it happen. Right away, the baby started crying, and his dad noticed some concerning signs like his eyes moving strangely, his skin turning blue, and him feeling limp and not fully awake. They rushed him to a big hospital, and on the way there, he seemed to get better and acted like his normal self again.

When they got to the hospital, a children's doctor did a scan of his head and saw a thin area of bleeding called an acute subdural hematoma (ASDH) measuring up to 2 mm (Figure 6). Even though there weren't any other signs of injury or brain problems, they decided to keep an eye on him. They did lots of tests, like checking his bones and blood, and everything looked normal. But two days later, they found bleeding in his eyes called retinal hemorrhages (Figure 7).

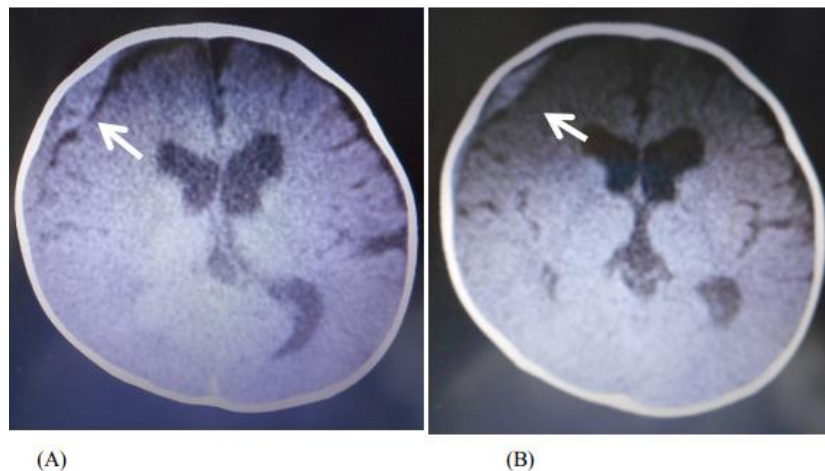


**Figure 6:** On the day of the injury, a CT scan showed a thin, dense area of bleeding just under the skull, measuring up to 2 mm thick on the right side of the brain (indicated by the arrow). Also, notice the enlarged spaces around the brain called subarachnoid spaces and the fluid-filled areas called ventricles.



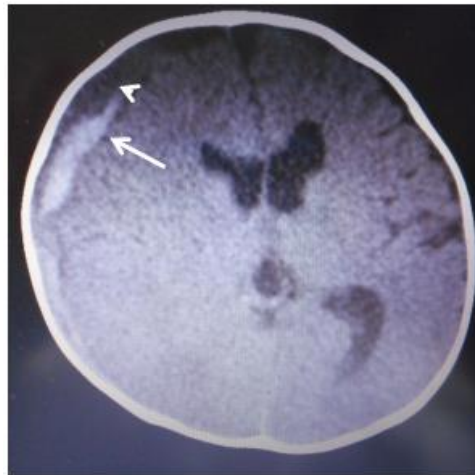
**Figure 7:** On Day 2, when the doctor looked at the back of the baby's eyes using a special tool called a fundoscope, they saw some small bleeding spots in the retinas located at the back of the eyes. These spots were found near the back of the head on both sides: on the left side (A) and the right side (B).

For a few days, things seemed okay, but then on Day 6, he had another fall, this time in the hospital's special children's bed. He hit his head against the metal railing, and an ICU nurse saw it happen. Right after, the baby got really upset and showed some worrying signs like his eyes moving strangely, his skin turning blue, and his body getting stiff. His heart rate dropped for a bit but then went back to normal. They quickly gave him medicine and oxygen to help.




**Figure 8:** *In the follow-up CT scans, we can see that the dense area of bleeding under the skull got bigger on Day 3 (pointed by the arrow), and then it got smaller again on Day 4 (also pointed by the arrow). We have two images: one from Day 3 (A) and one from Day 4 (B).*

Emergency scans showed a mix of different densities in the bleeding in his head (Figure 9), and eye doctors found more bleeding in his eyes (Figure 10). Thankfully, the bleeding in his head got better on its own, and after five days, he was doing well without any lasting problems. A later scan showed that his brain was okay, except for the leftover blood from the injury. Two years later, he was hitting all his normal milestones, showing that he had recovered fully.



**Figure 9:** *The CT scan taken on Day 6 right after the accident shows that the area of bleeding under the skull got bigger. There are two types of bleeding seen: one is denser (pointed by the arrow) and the other is less dense (pointed by the arrowhead).*



(A)

(B)

*Figure 10: On Day 6 after the accident, when the doctor looked at the back of the baby's eyes using a special tool called a fundoscope, they found new bleeding spots in the retinas located at the back of the eyes. These spots were seen on both sides: on the left side (A) and the right side (B).*

## **Discussion**

Let's dive into a discussion that goes back over thirty years, starting with a study published in the Journal of Neurosurgery by Aoki and Masuzawa. They talked about infantile acute subdural hematoma (i-ASDH), which they defined as bleeding around the brain in infants caused by minor head injuries without loss of consciousness or severe brain damage. However, some people criticized them, saying that the cases they talked about were actually from shaken baby syndrome and were cases of child abuse.

The idea that i-ASDH might be a separate condition hasn't been widely accepted, especially in English-speaking countries. But in Japan, they've recognized for over thirty years that minor head injuries are the most common cause of ASDH in infants, with about 120 cases reported every year.

In the United States and other countries, i-ASDH isn't well-known because most reports of it come from Japan. Instead, cases like these might be diagnosed as shaken baby syndrome or abusive head trauma because they're so rare and people are more used to seeing ASDH from abusive situations.

In Japan, there have been over 200 cases of i-ASDH reported in 14 articles. But because most of these articles are in Japanese, their findings aren't widely known outside of Japan.

There are a few key differences between i-ASDH and shaken baby syndrome/abusive head trauma. First, most cases of i-ASDH have a good outcome, with about 80% of patients recovering well. Second, i-ASDH mostly happens in boys between 6 and 12 months old, and these accidents usually happen at home and aren't witnessed by anyone. Lastly, unlike shaken baby syndrome, i-ASDH doesn't usually involve severe brain damage, which is shown by imaging tests and surgeries.

While retinal hemorrhages are often seen as a sign of child abuse, cases like this one show that they can also happen with i-ASDH, adding to the complexity of diagnosing these cases.

## **"Infantile" Acute Subdural Hematoma: A Distinct Clinical Entity Separate from Abusive Head Trauma**

It's been over thirty years since Aoki and Masuzawa published an article titled "Infantile" acute subdural hematoma: Clinical analysis of 26 cases in the Journal of Neurosurgery. In their study, they looked at cases of acute subdural hematomas (ASDH) in babies, but they only included cases caused by minor head injuries without the baby losing consciousness or having a primary brain

injury. Some experts criticized their findings, saying that the combination of ASDH and retinal hemorrhage should automatically be seen as shaken baby syndrome unless proven otherwise.

In response to this criticism, Aoki and his team pointed out that in Japan, the most common form of child abuse involves direct violence, leading to visible signs of trauma and a poor outlook for the baby's brain health. They argued that this is different from the cases they studied, which didn't involve such clear signs of abuse.

*Table 1: Comparing How Babies Recover from i-ASDH and AHT.*

	i-ASDH		AHT	
	Aoki & Masuzawa [1], 1984	Nishimoto & Kurihara [8], 2006	Golden & Maliawan [9], 2004	Kivlin, et al. [10], 2000
	(n = 26)	(n = 25)	(n = 39)	(n = 92)
Good	22 (85%)	18 (72%)	9 (23%)	22 (24%)
Moderate disability	2 (8%)	7 (28%)	8 (20%)	8 (9%)
Severe disability	0	0	10 (26%)	26 (28%)
Dead	2 (8%)	0	12 (31%)	36 (40%)

*Table 2: Comparing How Babies Recover from i-ASDH and AHT Using Statistics.*

	Chi-square value	Fisher direct probability	Probability
Aoki & Masuzawa [1], 1984 vs. Kivlin, et al. [10], 2000		0	P < 0.001
Aoki & Masuzawa [1], 1984 vs. Nishimoto & Kurihara [8], 2006		0.324	N.S
Aoki & Masuzawa [1], 1984 vs. Golden & Maliawan [9], 2004		0	P < 0.001
Nishimoto & Kurihara [8], 2006 vs. Kivlin, et al. [10], 2000	661.611		P < 0.001
Kivlin, et al. [10], 2000 vs. Golden & Maliawan [9], 2004	0.397		N.S.
Nishimoto & Kurihara [8], 2006 vs. Golden & Maliawan [9], 2004	372.53		P < 0.001

However, despite their arguments, their idea of "infantile" ASDH hasn't been widely accepted, especially in English-speaking countries. Aoki now wants to ask some questions to Dr. Rekate and other neurosurgeons in the United States: first, whether they still automatically link ASDH and retinal hemorrhage to shaken baby syndrome or abusive head trauma, and second, whether there's solid evidence supporting the idea that minor falls in babies can't cause ASDH.

The goal of Aoki's presentation is to reintroduce the concept of "infantile" ASDH as a distinct condition, different from abusive head trauma, based on comparisons between the two and recent cases from Japan. Additionally, they want to propose a new classification system for ASDH in babies, dividing cases into three groups: non-accidental, accidental, and "infantile" types.

## Understanding Infantile Acute Subdural Hematoma (i-ASDH) in Japan

In Japan, more cases of a mild form of infantile acute subdural hematoma (i-ASDH) are being discovered due to routine CT scans done for infants with head injuries, even minor ones. These cases often involve thin bleeding under the skull and don't cause any symptoms after the baby has convulsions. Many of these babies also have bleeding in the back of their eyes when they arrive at the emergency room.

Here's an example: A Japanese baby boy, aged between 5 to 12 months, falls and hits the back of his head against a soft surface, like the corner of a table, while trying to stand up. Right after the fall, he starts crying, and his mom sees him having convulsions. They rush him to the emergency room, where a CT scan shows he has an acute subdural hematoma. They also notice bleeding in his eyes. Shortly after, he's back to his normal self, with no lasting problems.

*Table 3: Looking at the Ages of Babies with i-ASDH and AHT.*

Age (months)	1	2	3	4	5	6	7	8	9	10	11	12	13	14	15	16	17
<b>i-ASDH No. of case</b>																	
Aoki & Masuzawa [1], 1984 (n = 26)	0	0	1	1	1	1	6	6	2	5	2	0	1	0	0	0	0
Nishimoto & Kurihara [8], 2006 (n = 25)	0	0	0	0	0	3	8	5	3	4	1	0	0	0	0	0	1
<b>AHT No. of case</b>																	
Kivlin, et al. [10], 2000 (n = 92)	9	13	18	15	6	10	7	4	1	6	3	3	3	1	2	1	0
Golden & Maliawan [9], 2004 (n = 39)	19	16	1	1	2	0	0	0	0	0	0	0	0	0	0	0	0

It's interesting to note that the stories told by the mothers of these babies are very similar, even though they wouldn't have known about i-ASDH before going to the hospital.

There are three main differences between i-ASDH and abusive head trauma (AHT). First, i-ASDH usually has a good outcome, with about 80% of patients recovering well. Second, it mostly happens in babies between 5 to 12 months old, and it's much more common in boys. Third, there's no evidence of any other brain injuries when they do CT scans, MRIs, or surgeries, and the babies usually recover fine even without surgery.

It's crucial to tell the difference between i-ASDH and AHT because the consequences of getting it wrong can be very serious. The way accidental subdural hematomas happen, like in car accidents or falls from high places, is similar to AHT, where there's usually some kind of serious injury to the brain. But i-ASDH is different because it happens without any other brain injuries, usually from just a minor bump.

*Table 4: Comparing the Ages of Babies with i-ASDH and AHT Using Statistics.*

	<b>Z value</b>	<b>probability</b>
Aoki & Masuzawa [1], 1984 vs. Kivlin, et al. [10], 2000	4.042	< 0.001
Aoki & Masuzawa [1], 1984 vs. Nishimoto & Kurihara [8], 2006	0.211	N.S.
Aoki & Masuzawa [1], 1984 vs. Golden & Maliawan [9], 2004	12.075	< 0.001
Nishimoto & Kurihara [8], 2006 vs. Kivlin, et al. [10], 2000	4.286	< 0.001
Kivlin, et al. [10], 2000 vs. Golden & Maliawan [9], 2004	6.876	< 0.001
Nishimoto & Kurihara [8], 2006 vs. Golden & Maliawan [9], 2004	13.670	< 0.001

To make sure i-ASDH is recognized as its own thing, we need to come up with a new way to classify subdural hematomas in babies, splitting them into accidental, non-accidental, and "infantile" types.

## **Conclusion**

In conclusion, the work of Nobuhiko Aoki sheds light on the increasing recognition of infantile acute subdural hematoma (i-ASDH) in Japan, especially due to the routine use of CT scans for assessing head injuries in infants. This condition, characterized by mild subdural hematomas and retinal hemorrhages following seemingly minor head trauma, presents a distinct clinical profile, often with a favorable outcome. Aoki emphasizes the importance of differentiating i-ASDH from abusive head trauma (AHT) due to significant differences in prognosis, age specificity, and underlying pathology.

Aoki's research proposes a new classification system for subdural hematomas in infants, aiming to establish i-ASDH as a definite patho-etiological entity alongside non-accidental and accidental cases. This classification system not only aids in medical diagnosis and management but also holds legal implications, highlighting the necessity for accurate medical evidence in cases involving head trauma in infants. Aoki's contributions underscore the significance of international collaboration and standardized diagnostic criteria in understanding and managing i-ASDH.

# Chapter 8

## Neuroimaging in Neurosurgery: From Diagnosis to Postoperative Care

### Role of MRI in Differentiating Extracerebral Fluid Collections

MRI, or magnetic resonance imaging, plays a crucial role in distinguishing various types of fluid collections that occur outside the brain, known as extracerebral fluid collections. These collections can be caused by different conditions such as trauma, infection, or bleeding. MRI utilizes powerful magnets and radio waves to create detailed images of the body's internal structures, including the brain and surrounding areas. By analyzing these images, doctors can differentiate between different types of fluid collections based on their characteristics. For example, MRI can help distinguish between subdural hematomas, which are collections of blood outside the brain's covering, and other fluid collections like hygromas or seromas, which are typically clear fluids that accumulate due to injury or surgery. Additionally, MRI can provide information about the size, location, and any associated complications of these fluid collections, aiding in treatment decisions and patient management. Overall, MRI serves as a valuable tool in accurately diagnosing and distinguishing extracerebral fluid collections, guiding appropriate medical interventions for patients.

### Serial Neuroimaging in Sotos Syndrome

Serial neuroimaging in Sotos syndrome involves the repeated use of imaging techniques like MRI or CT scans to monitor changes in the brain over time in individuals with Sotos syndrome. Sotos syndrome is a genetic disorder characterized by rapid growth in early childhood, distinctive facial features, and often developmental delays. Neuroimaging helps doctors track any structural abnormalities or changes in the brain that may occur as the individual grows and develops. By conducting these imaging studies at different intervals, doctors can assess the progression of the syndrome, identify any potential complications, and tailor treatment plans accordingly. Serial neuroimaging plays a crucial role in understanding how Sotos syndrome affects the brain over time and in providing timely interventions to support the individual's health and development.

### Serial Neuroimaging Investigations in Sotos Syndrome (Cerebral Gigantism Syndrome)

Sotos syndrome, also known as cerebral gigantism syndrome, presents with a range of anomalies, including macrocephaly (an abnormally large head) with a prominent forehead, coarse facial features, prenatal onset of excessive growth leading to a relatively large body size, and large hands and feet. Additionally, individuals with Sotos syndrome may experience psychological retardation. While the condition's characteristic features have been recognized, detailed analysis of specific aspects such as macrocephaly has been lacking. Recently, Nobuhiko Aoki and colleagues encountered two patients with Sotos syndrome whose neuroimaging studies could be followed from birth onwards.

By examining the progression of neuroimaging findings in these patients, Aoki and his team aimed to gain deeper insights into the neurological aspects of Sotos syndrome. This chapter will delve into their findings, shedding light on the role of serial neuroimaging studies in understanding the neurological manifestations of Sotos syndrome and guiding clinical management strategies. Through meticulous observation and analysis, Aoki and his collaborators contribute to the growing body of knowledge surrounding this complex genetic disorder, ultimately aiming to improve outcomes for individuals affected by Sotos syndrome.

## **Patients and Methods**

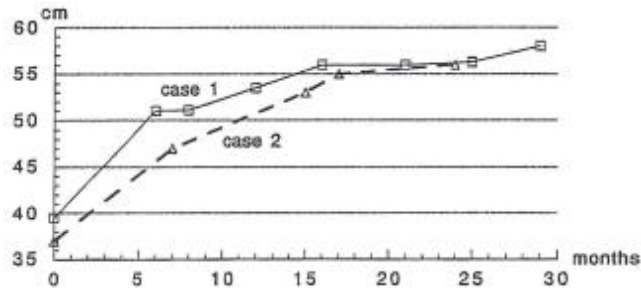
In this study, we're focusing on two male patients diagnosed with Sotos syndrome. This diagnosis is based on several key signs, including a very large head, distinct facial features, fast growth, big hands and feet, delayed development, and other typical abnormalities.

To track their progress, we monitored their head size over time, using a technique called macrocephaly measurement. We also conducted regular CT scans and MRIs of their heads. These imaging methods help us see detailed pictures of the brain and its structures.

We followed each patient for 24 and 29 months, respectively, to observe any changes in their condition.

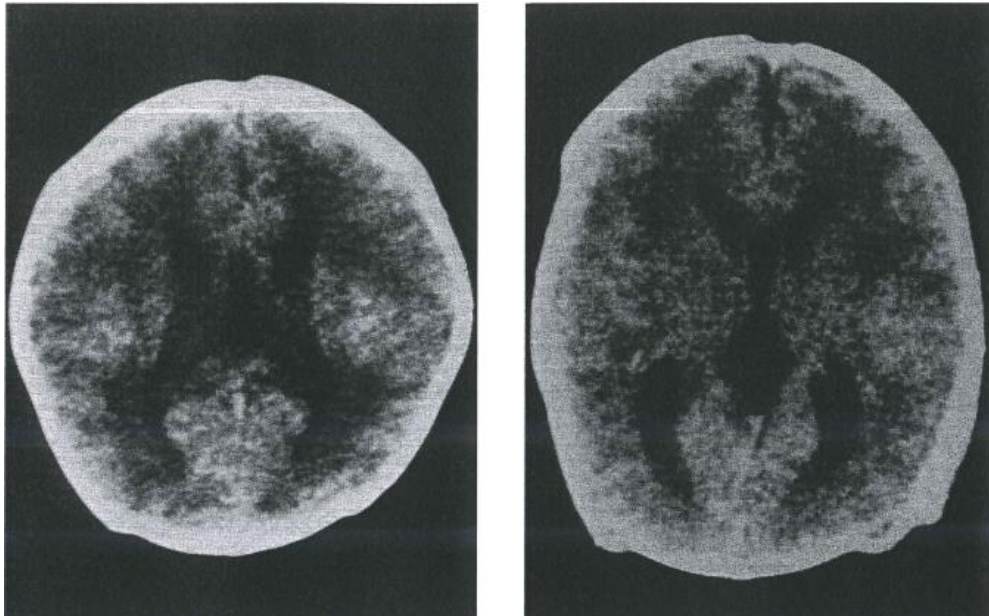
## **Results**

We measured the head size of both patients over time, and the results are shown in Figure 1. Throughout the observation period, the head circumference of both patients was consistently larger than what's typically expected for their age.



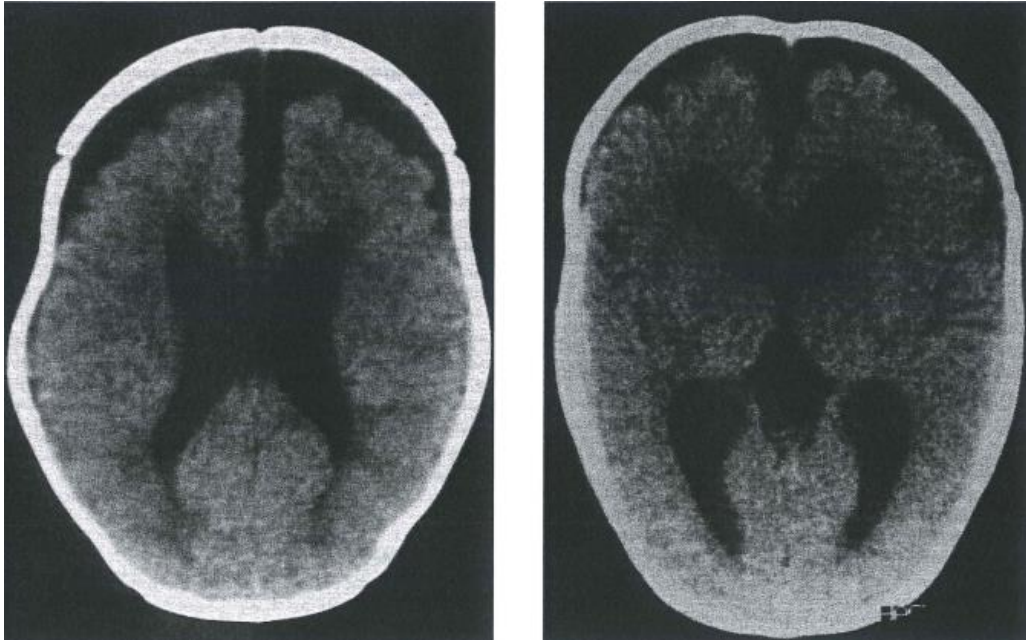
*Figure 1 shows a graph where we tracked the size of the head over time. It indicates that the head size is consistently larger than what's typically expected, surpassing the normal range by 2 standard deviations.*

Early CT scans taken shortly after birth revealed that both patients had larger-than-normal brain tissue (megalencephaly) and moderately enlarged ventricles (fluid-filled spaces within the brain) without any significant expansion of the spaces around the brain (subarachnoid spaces). You can see these findings in Figure 2.



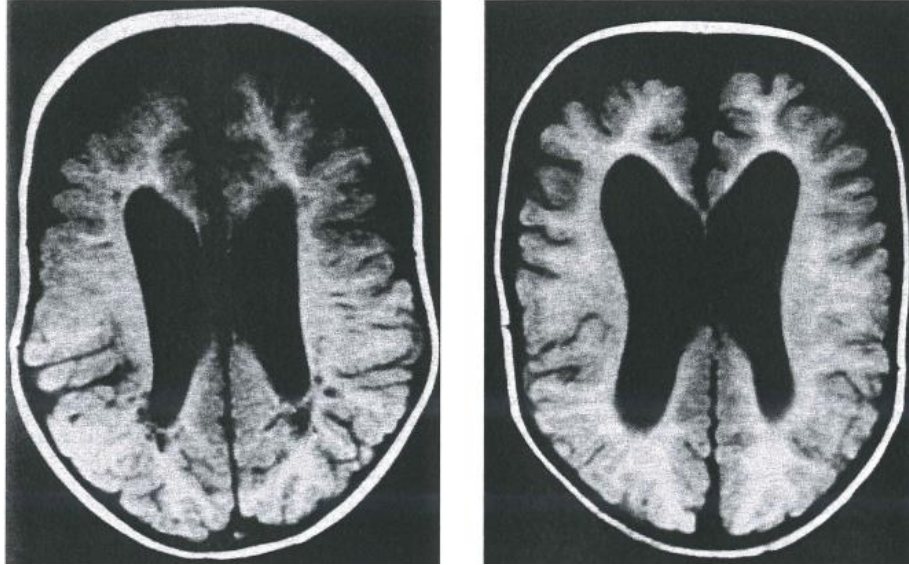
*Figure 2 displays two images from CT scans taken when the patients were 4 days old (left, Case 1) and 10 days old (right, Case 2). These scans show that there is mild enlargement of the brain ventricles, but there are no signs of fluid collecting outside the brain.*

Around six months later, a follow-up CT scan showed a significant increase in the amount of fluid outside the brain (extracerebral fluid collection), along with a slight progression in ventricular enlargement, as depicted in Figure 3.



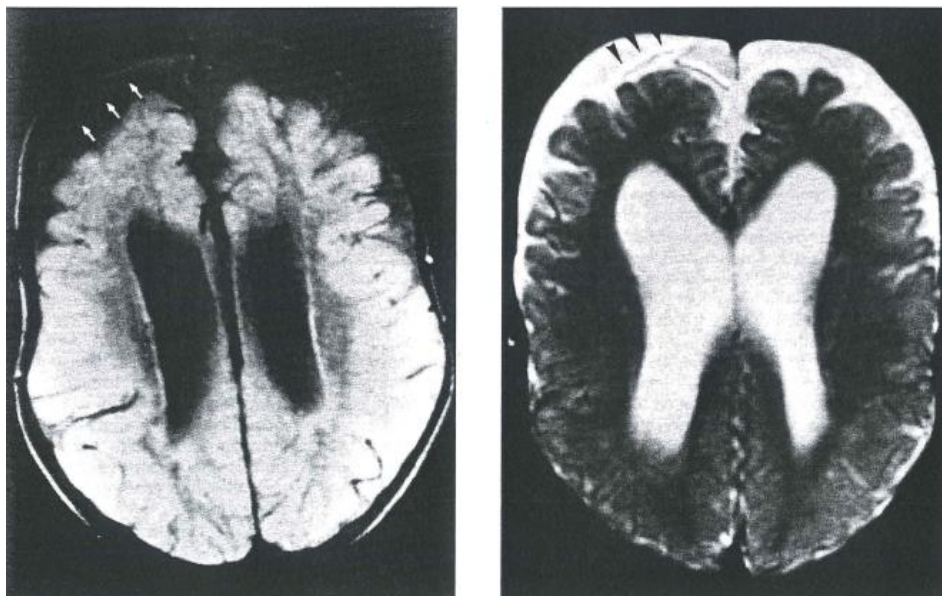*Figure 3 shows two images from CT scans taken when the patients were 5 months old (left, Case 1) and 6 months old (right, Case 2). These scans reveal that the brain ventricles are moderately enlarged, and there is also evidence of fluid collecting outside the brain.*

When we conducted MRI scans at the age of one year, we observed further enlargement of the ventricles and a more noticeable extracerebral fluid collection, as shown in Figure 4.



*Figure 4 displays two images from MRI scans taken when the patients were 12 months old (left, Case 1) and 13 months old (right, Case 2). These images reveal that the brain ventricles are even larger than before, and there is a noticeable increase in the amount of fluid collecting outside the brain.*

By the time the patients were 16 months old, the extracerebral fluid collection appeared similar in density to cerebrospinal fluid (the fluid that surrounds the brain and spinal cord). Additionally, we noticed areas in the fluid where blood vessels were visible, indicating vascular flow. You can see these details in Figure 5.



*Figure 5 shows two images from MRI scans taken when the patients were 16 months old. The image on the left (Case 1) uses a technique called proton weighting, while the image on the right (Case 2) uses T2 weighting. These images reveal that the fluid collecting outside the brain appears similar in density to cerebrospinal fluid, and there are areas within the fluid where blood vessels are visible (indicated by arrowheads and arrows).*

## **Discussion**

Even though having a large head (macrocephaly) is a common feature of Sotos syndrome, there haven't been many studies following patients over time. Until now, it hasn't been clear whether the excess brain tissue (megalencephalon) or fluid build-up inside the head contributes to this condition. In the past, when CT scans were the primary imaging tool, doctors noted that Sotos syndrome often involves enlarged brain ventricles and fluid collections outside the brain. However, there hasn't been much information about these changes, especially in newborns.

Our study found that right after birth, the large head size in Sotos syndrome is mainly because of the excess brain tissue and slightly enlarged ventricles. But as time goes on, the head gets bigger due to fluid building up inside the head, especially around the brain. This fluid collection, particularly outside the brain, is a significant factor in the head enlargement seen in Sotos syndrome.

In previous studies using high-resolution CT scans, it was hard to tell apart these fluid collections from other types of fluid build-up in the head. However, in our study using MRI, we found that this fluid outside the brain is similar to cerebrospinal fluid and doesn't represent other types of fluid build-up like subdural effusions. This means that the enlargement of the spaces around the brain, not fluid trapped under the brain's coverings, is the main reason for the head enlargement in Sotos syndrome.

In summary, as Sotos syndrome progresses, the initial increase in head size is due to the excess brain tissue. Later on, the enlargement happens because of fluid build-up in the spaces around the brain and inside the ventricles.

## **Conclusion**

In summary, the research conducted by Dr. Nobuhiko Aoki and colleagues sheds light on the progression of Sotos syndrome, particularly focusing on the neurological aspects. Through careful observation and analysis of serial neuroimaging studies, the team uncovered valuable insights into the underlying mechanisms contributing to macrocephaly (enlarged head) in Sotos syndrome.

Their findings indicate that macrocephaly in Sotos syndrome initially stems from an excess volume of brain tissue, specifically megalencephaly, and mild ventriculomegaly. However, as the

syndrome progresses, the enlargement of the head becomes increasingly associated with the accumulation of fluid outside the brain, particularly in the subarachnoid spaces.

This study not only provides a clearer understanding of the neurological manifestations of Sotos syndrome but also highlights the importance of utilizing advanced imaging techniques such as CT and MRI in monitoring disease progression and guiding clinical management strategies.

By elucidating the mechanisms underlying macrocephaly in Sotos syndrome, Dr. Nobuhiko Aoki and his team contribute to the growing body of knowledge aimed at improving the diagnosis, treatment, and overall outcomes for individuals affected by this rare genetic disorder. Their work underscores the significance of interdisciplinary collaboration between clinicians, geneticists, and neuroimaging experts in unraveling the complexities of genetic syndromes and advancing patient care.

Dr. Nobuhiko Aoki's expertise and leadership in the field of neuroimaging have been instrumental in advancing our understanding of Sotos syndrome. His dedication to unraveling the complexities of this rare genetic disorder through meticulous research has paved the way for improved diagnostic and therapeutic strategies, ultimately benefiting individuals and families affected by Sotos syndrome worldwide.

# Chapter 9

## Complications in Neurosurgery: Prevention and Management

### Postoperative Complications: Case Studies and Management

Postoperative complications can happen after surgery, causing problems for patients during recovery. Let's imagine a few cases to understand them better. First, let's talk about Mrs. Smith, who had surgery on her abdomen. After the procedure, she developed an infection at the incision site. This is a common complication called a surgical site infection (SSI). Doctors treated her with antibiotics to clear the infection and helped her wound heal properly.

Next, there's Mr. Johnson, who underwent heart surgery. Unfortunately, he experienced a complication called atrial fibrillation, where his heart rhythm became irregular. To manage this, doctors gave him medications to control his heart rate and prevent blood clots.

Lastly, let's consider young Sarah, who had a routine appendectomy. Despite the surgery going smoothly, she developed a blood clot in her leg afterward. This complication, known as deep vein thrombosis (DVT), required blood-thinning medications and compression stockings to prevent further clotting and complications like pulmonary embolism.

In each of these cases, managing complications involved a combination of medications, monitoring, and sometimes further procedures. Postoperative care plays a crucial role in identifying and addressing these complications promptly, ensuring patients recover safely and smoothly.

### Postoperative Inflammatory Response Resulting in Focal but Severe Brain Edema

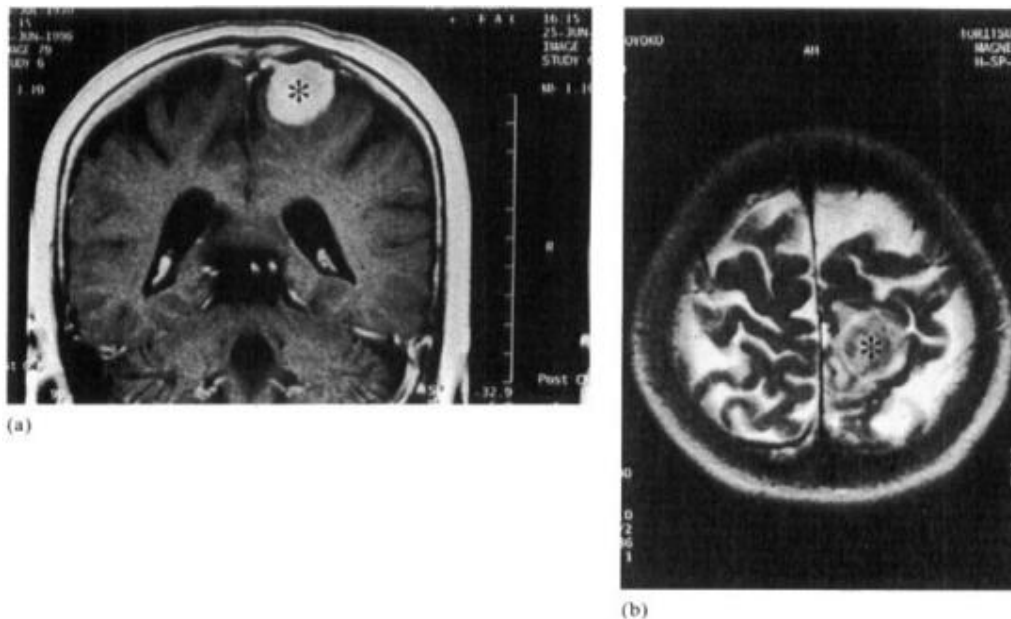
In the realm of neurosurgery, complications following intracranial procedures can pose significant challenges to patients and healthcare providers alike. One well-recognized complication is the development of foreign body granulomas, typically occurring months after surgery when nonabsorbable materials are utilized. However, recent reports from Japan have shed light on another potential culprit: microfibrillar collagen, an absorbable hemostatic agent, causing symptomatic granuloma formation in the early postoperative period.

In a notable account by Nobuhiko Aoki and colleagues, a postoperative complication emerged merely four days after the intracranial application of Biobond-soaked oxycellulose. This unprecedented event led to the manifestation of focal but severe brain edema, as revealed by neuroimaging studies. Such occurrences underscore the importance of vigilance in recognizing and managing complications promptly.

This chapter delves into the intricacies of this rare complication, providing insights gleaned from firsthand experience. By elucidating the details of this phenomenon, the aim is to enhance understanding and awareness among neurosurgical practitioners worldwide.

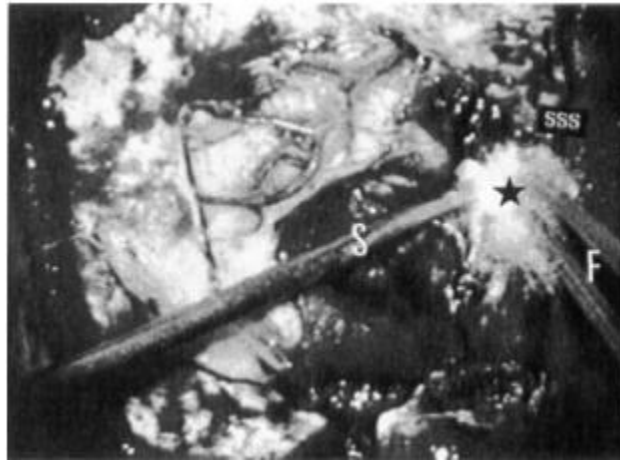## Case report

A 66-year-old woman, managing her hypertension well, suddenly lost consciousness for about 5 minutes on June 6, 1996. Since no one witnessed the event, details remained unclear. She was taken to a nearby hospital where a computed tomography (CT) scan revealed an intracranial mass. Subsequently, she was referred to the Department of Neurosurgery at Tokyo Metropolitan Ohkubo Hospital. Physical and neurological examinations upon arrival showed no abnormalities. Magnetic resonance (MR) imaging indicated a mass lesion, likely a meningioma, in the left frontal region.



*Figure 1 shows images taken before the surgery using magnetic resonance (MR). In the images, you can see a mass (marked with an asterisk) along with a little bit of swelling around it.*

Her loss of consciousness remained unexplained despite normal results from electroencephalogram and Holter electrocardiogram tests. Initially, surgical intervention wasn't considered necessary. However, due to persistent requests from the patient and her husband, surgery was scheduled to remove the tumor. Preoperative tests showed normal results. On August 7, 1996, the patient underwent left frontoparietal craniotomy to remove the tumor completely. During surgery, bleeding from the superior sagittal sinus was controlled using Biobond-soaked oxycellulose.

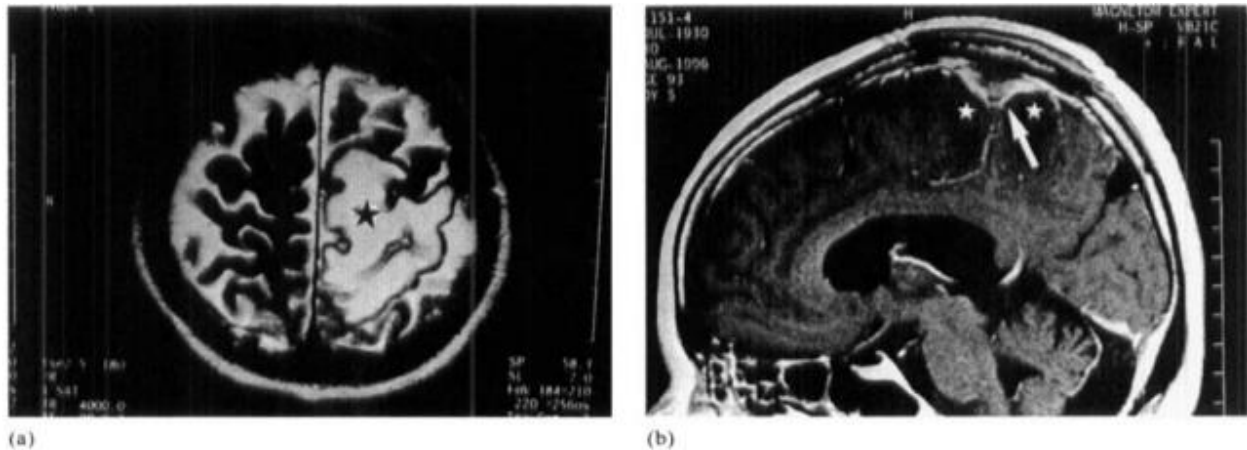


*Figure 2 shows a photo taken during surgery. It depicts the application of a small piece of Biobond-soaked oxycellulose (marked with a star) to the side of the superior sagittal sinus. You can see that the amount of Biobond-soaked oxycellulose is quite small in comparison to the size of the sucker, which is about 4 millimeters in diameter. In the image, you can also see forceps and the superior sagittal sinus labeled as SSS.*

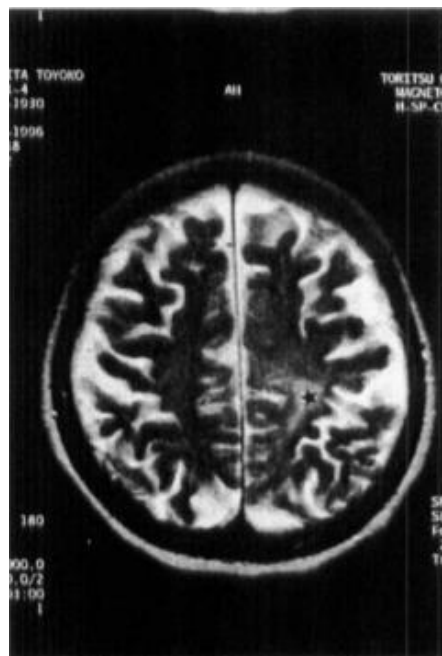The tumor was confirmed to be a transitional meningioma upon histological examination. Postoperatively, she didn't experience any sensory or motor deficits but was given phenobarbital to prevent seizures. However, on August 11, she started experiencing transient sensations of discomfort in her right lower limb, which worsened over time. Phenobarbital was discontinued on August 16 due to a drug eruption, but on August 21, she had a focal seizure in her right lower extremity, requiring administration of valproic acid. Despite treatment, her neurological deficits persisted, and MR imaging on August 29 revealed prominent edema in the left frontal region.

Further investigation suggested that the edema was a result of an inflammatory reaction to the hemostatic agent used during surgery. Treatment with intravenous steroids led to significant improvement, and the patient was discharged on September 28, 1996, with resolution of her symptoms. Follow-up examinations over the next year showed no recurrence of symptoms.

This case highlights the importance of recognizing and managing postoperative complications promptly to ensure optimal patient outcomes. (Figures and tables referenced in the original text are not included here.)



*Figure 3 shows images taken 22 days after surgery using magnetic resonance (MR). In the images, you can see a significant area of swelling (marked with a star) in one picture (a), and in another picture (b), there's a bright spot (marked with an arrow) along with swelling around it (marked with stars).*



*Figure 4 displays an image taken using magnetic resonance (MR) one week after surgery. In this image, you can observe a significant reduction in swelling (marked with a star).*

## **Discussion**

In this discussion, we'll break down the case and its implications. Although we didn't confirm the cause of the brain swelling through surgery, the swelling matched where we applied a specific surgical material during the operation. This strongly suggests that the swelling was caused by that material.

Recently, similar materials, like microfibrillar collagen, have been reported to cause swelling soon after surgery. But cases like ours, where oxycellulose causes swelling, are rare. Usually, if oxycellulose causes swelling, it happens much later, not early like in our case.

The material we used, Biobond-soaked oxycellulose, has been used in many brain surgeries without issues. So, it's likely that the swelling was caused by Biobond rather than oxycellulose because it started early and wasn't a large swelling. This kind of complication hasn't been reported before.

Our observation fits with what's known about how inflammation affects the brain's surface more than its deeper parts. Although we've used Biobond-soaked oxycellulose before without problems, seeing this swelling on the brain scan made us consider other causes like a blood clot or infection. But tests ruled those out, and treatment with steroids and glycerol helped the swelling go down.

Fortunately, the patient recovered well with treatment, but we planned to remove the Biobond-soaked oxycellulose if the swelling got worse. Since this complication hasn't been reported before, it's important to share this case. Also, our experience shows that starting steroids early might help if Biobond causes inflammation.

## **Cerebrovascular Bypass Surgery: Risks and Outcomes**

Cerebrovascular bypass surgery is a procedure aimed at improving blood flow to the brain by creating alternative routes for blood to travel when the usual vessels are blocked or narrowed. Like any surgery, it carries risks, but it can also lead to positive outcomes. During the procedure, the surgeon uses a blood vessel from another part of the body or a synthetic graft to reroute blood flow around the blocked or damaged blood vessels in the brain. Risks associated with cerebrovascular bypass surgery include bleeding, infection, stroke, and complications related to anesthesia. However, for many patients, the potential benefits outweigh these risks. By restoring adequate blood flow to the brain, bypass surgery can help prevent strokes, reduce the risk of further damage to brain tissue, and improve overall brain function. Postoperative care and rehabilitation are essential for maximizing the chances of a successful outcome, and close monitoring by healthcare providers is crucial during the recovery period. Overall, while cerebrovascular bypass surgery involves risks, it can be a vital intervention for individuals with certain cerebrovascular conditions, offering the potential for improved quality of life and long-term outcomes.

# **Cerebrovascular Bypass Surgery in Moyamoya Disease: Suboptimal Outcome in Patients Presenting with Intracranial Hemorrhage**

Cerebrovascular bypass surgery has shown to be effective in treating pediatric patients with Moyamoya disease who experience cerebral ischemia. However, when it comes to adult patients with Moyamoya disease who suffer from intracranial hemorrhage, there's still uncertainty about whether bypass surgery is the right course of action. Intracranial hemorrhages in Moyamoya disease are typically found within the brain or in the ventricles. Since these bleeds are linked to the development of collateral vessels in Moyamoya disease, bypass surgery is considered a potential way to reduce the risk of future bleeds by easing the strain on these fragile vessels.

Despite the theoretical promise of bypass surgery in preventing recurrent hemorrhages, its long-term effects remain unclear. This is a crucial aspect that needs urgent clarification and is currently a major area of interest for neurosurgeons, particularly in Japan. Over the past nine years, Nobuhiko Aoki, the author of this study, has performed indirect (nonanastomotic) cerebrovascular bypass surgery for both ischemic and hemorrhagic types of Moyamoya disease. In this study, the outcomes of bypass surgery for Moyamoya disease presenting as intracranial hemorrhage are examined, focusing on clinical and neuroradiological aspects, with special attention to the occurrence of rebleeding. Additionally, the study critically evaluates the rationale behind the effectiveness of bypass surgery for the hemorrhagic type of Moyamoya disease. This comprehensive analysis aims to shed light on the role of bypass surgery in treating Moyamoya disease with intracranial hemorrhage and to provide valuable insights for future treatment decisions.

## **Patients and Methods**

Between 1982 and 1990, Tokyo Metropolitan Fuchu Hospital admitted 18 patients with Moyamoya disease. This study focused on two pediatric patients and ten adult patients who experienced sudden intracranial hemorrhage. The two pediatric patients, both females aged 9 and 11 years, underwent surgery known as encephaloduroarteriosynangiosis (EDAS). Among the adult patients, aged between 26 and 61 years, five underwent indirect bypass surgery. One patient had bilateral EDAS, two had bilateral encephalomyosynangiosis (EMS), one had unilateral EMS, and one had EDAS on one side and EMS on the other side.

After surgery, follow-up angiography was done to check how well new blood vessels were forming and any changes in Moyamoya vessels. The focus was on whether there were any cases of rebleeding during follow-up. Table 1 summarizes the characteristics of these patients. Five adult patients didn't undergo surgery and were instead monitored without intervention. They included one male and four females, aged between 34 and 63 years. Their clinical details and follow-up outcomes are listed in Table 2.

*Table 1: Details of Seven Patients with Moyamoya Disease who Underwent Bypass Surgery*

Case No.	Age/Sex (yrs)	Clinical manifestations	Bypass procedure	Angiographic evaluation					Moyamoya vessels	Follow-up period (yr)	Outcome
				Side	Stage <sup>a</sup>	Postoperative period	Revascularization <sup>b</sup>				
1	7/F	IVH	R. (ND) L. EDAS	R. L.	III III	13 mos	no	Unchanged	10	No rebleeding, moderately disabled	
2	11/F	IVH	Bil. EDAS	R. L.	III III	3 yrs 3 yrs	no no	Unchanged	11	No rebleeding, moderately disabled	
3	40/F	IVH	Bil. EMS	R. L.	III III	2 yrs 2 yrs	no no	Unchanged Unchanged	7	No rebleeding, asymptomatic	
4	26/F	IVH	Bil. EMS	R. L.	III III	3 yrs 3 yrs	no no	Unchanged Unchanged	6	Rebleeding (IVH) 5 yrs after surgery, mildly disabled	
5	41/F	IVH	Bil. EDAS	R. L.	III V	9 mos 18 mos	no no	Unchanged Unchanged	2	No rebleeding, mildly disabled	
6	51/M	ICH	R. (ND) L. EMS	R. L.	III III	12 mos	fair	Reduced	5	No rebleeding, moderately disabled	
7	61/F	ICH	R. EDAS L. EMS	R. L.	III III	3 mos 3 mos	no no	Unchanged Unchanged	5	No rebleeding, moderately disabled	

*Table 2: Details of Five Patients with Moyamoya Disease who Were Monitored Without Bypass Surgery*

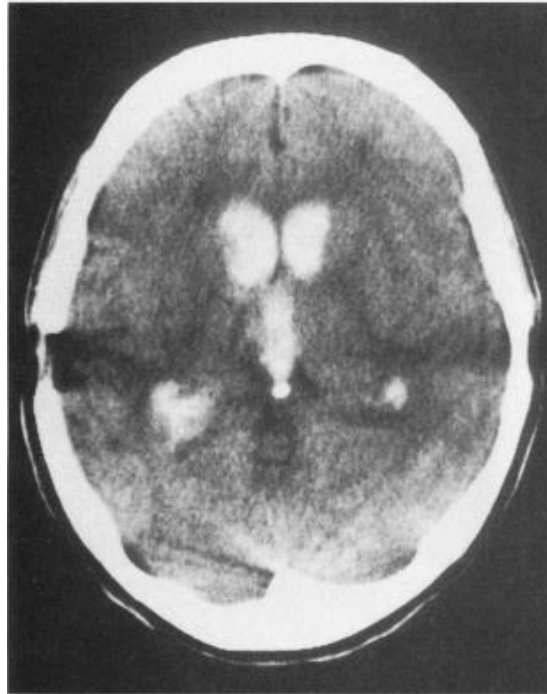
Case No.	Age/Sex	Clinical manifestations	Angiographic features		Follow-up period	Outcome
			Side	Stage <sup>a</sup>		
1	63/F	ICH	R. L.	V V	5 yrs	Rebleeding (ICH) one year later, severely disabled
2	50/M	ICH	R. L.	IV IV	4 yrs	No rebleeding, aphasia, hemiparesis
3	44/F	ICH	R. L.	VI VI	4 yrs	No rebleeding, hemiparesis, severely disabled
4	34/F	IVH	R. L.	III III	4 yrs	No rebleeding, asymptomatic
5	47/F	IVH	R. L.	V IV	4 yrs	Rebleeding (IVH) 3yrs later, asymptomatic

## Results

### *Clinical Follow-up*

During the follow-up period, which ranged from 2 to 11 years with an average of 4.9 years, seven patients who had bypass surgery were monitored. One adult patient (Case 4 in Table 1) experienced another episode of bleeding into the ventricles five years after the procedure (see Figure 5). This

resulted in lasting neurological issues, including weakness in the right eye muscles and difficulties with thinking. Fortunately, there were no complications directly related to the bypass surgery in any of these seven patients.

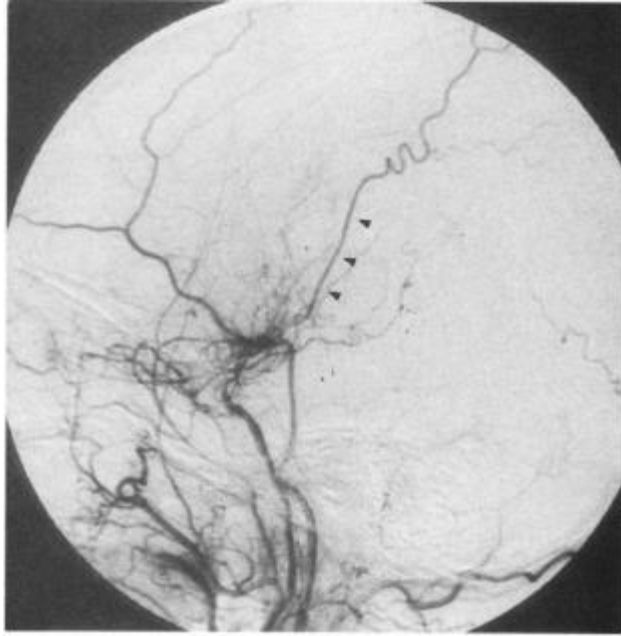


*Figure 5: A CT scan of Case 4 from the bypass surgery group, displaying another instance of bleeding into the ventricles 5 years after encephalomyosynangiosis.*

However, among the five patients who didn't undergo surgery and were monitored without intervention, two experienced rebleeding episodes. One had bleeding into the ventricles, and the other had bleeding within the brain tissue. These occurred 1 and 3 years after the initial bleeding episode, respectively, during the 4- to 5-year study period. While one of these patients fully recovered, the other remained severely disabled.

#### ***Angiographic Follow-up:***

After the bypass surgery, final follow-up angiography was done between 3 and 36 months later, with an average of 20.8 months. Only one out of the seven patients (Case 6 in Table 1) showed significant improvement in blood vessel formation and a reduction in Moyamoya vessels (see Figure 6).



*Figure 6: Left carotid angiography of Case 5 from the bypass surgery group, showing that there was no new blood vessel formation through the superficial temporal artery (indicated by arrows) 18 months after encephaloduroarteriosynangiosis.*

## **Discussion**

Moyamoya disease is typically diagnosed using cerebral angiography, a test that shows the blood vessels in the brain. In Japan, many patients with intracranial hemorrhage undergo this test, which helps identify Moyamoya disease. It's important to note that Moyamoya disease itself doesn't usually cause primary subarachnoid hemorrhage.

The presence of Moyamoya vessels in the brain is a key indicator of Moyamoya disease. These vessels can be seen on cerebral angiography not only in patients with ischemia (reduced blood flow) but also in those with intracranial hemorrhage (bleeding within the brain). While Moyamoya disease often presents as ischemia in children and hemorrhage in adults, there's debate about whether the disease is the same in both age groups. However, it's not uncommon for patients to experience ischemia in childhood and later have hemorrhage as adults.

Cerebrovascular bypass surgery aims to prevent the risk of further bleeding in patients with Moyamoya disease who have had hemorrhagic events. The success of this surgery can be evaluated through clinical and angiographical follow-up studies. It's important to compare the rate of rebleeding after surgery to the natural course of the disease. National surveys in Japan have shown that about 30% of patients experience recurrent bleeding over time.

**Table 3: Rate of Recurrent Bleeding in Patients with Moyamoya Disease Monitored Without Bypass Surgery in Previous Studies and in this Study**

Reference	Total number of patients	Follow-up period	Number of patients with rebleeding (%)
Kudo and Fukada [7]	58	A few yrs to 10 yrs	10 (17)
Nishimoto et al [14]	175	Not described	57 (33)
Yonekawa et al [22]	29	1 month to 10 yrs (mean 3.2 yrs)	9 (31)
Saeki et al [17]	18	2 wks to 18 yrs (mean 5.4 yrs)	5 (28)
Aoki (present study)	5	4 to 5 yrs	2 (40)

**Table 4: Rate of Recurrent Bleeding in Patients with Moyamoya Disease who Underwent Bypass Surgery in Previous Studies and in this Study**

Reference	Total number of patients	Bypass procedure	Number of patients with reduction of Moyamoya vessels after bypass surgery	Follow-up period	Number of patients with rebleeding (%)
Nishimoto et al [14]	14	ND	ND	ND	3 (21)
Nakagawa et al [13]	8	STA/MCA and EMS	ND	8 to 49 mos (mean 32 mos)	2 (25) <sup>a</sup>
Ishii [2]	6	ND	ND	ND	1 (17)
Yonekawa et al [22]	26	STA/MCA	60% of operative sides	mean 3.8 years	2 (8) <sup>b</sup>
Shimoji et al [19]	5	EDAS	2	ND	2 (40) <sup>b</sup>
Kobayashi et al [6]	4	STA/MCA	2	2 to 5 yrs (mean 3.8 yrs)	2 (50) <sup>b</sup>
Aoki (present study)	7	EDAS, EMS	1	2 to 11 yrs (mean 4.9 yrs)	1 (14) <sup>c</sup>

Studies have looked at the outcomes of bypass surgery. Some found that rebleeding still occurred in a portion of patients after surgery, suggesting that bypass surgery might not be entirely effective in preventing further bleeding. However, there's ongoing debate about which type of bypass surgery—direct or indirect—is more effective, with some studies showing favorable results with direct bypass surgery but others not. Overall, the effectiveness of bypass surgery in preventing recurrent bleeding remains uncertain.

Given the successful outcomes of bypass surgery for Moyamoya disease with cerebral ischemia, there's interest in understanding why the effectiveness of surgery might vary depending on whether the patient's symptoms are ischemic or hemorrhagic. Since recurrent bleeding significantly impacts the prognosis of Moyamoya patients, more effective treatment approaches are needed to reduce the risk of further bleeding.

## Conclusion

In conclusion, the discussion surrounding Moyamoya disease and its treatment with cerebrovascular bypass surgery highlights several key points. First, the diagnosis of Moyamoya disease relies on cerebral angiography, which can reveal the characteristic Moyamoya vessels in the brain. While the disease often presents differently in children and adults, with ischemia being common in children and hemorrhage in adults, there is overlap between the two groups.

Cerebrovascular bypass surgery is aimed at preventing recurrent bleeding in patients with Moyamoya disease who have experienced hemorrhagic events. However, the effectiveness of this surgery in preventing rebleeding remains uncertain. Studies have shown mixed results, with some patients experiencing rebleeding even after surgery. The type of bypass surgery, whether direct or indirect, also has varying outcomes, with no clear consensus on which is more effective.

Despite these uncertainties, it's clear that recurrent bleeding significantly impacts the prognosis of Moyamoya patients. More effective treatment approaches are needed to reduce the risk of further bleeding and improve patient outcomes.

Throughout this discussion, the work of author Nobuhiko Aoki stands out. Their studies have contributed valuable insights into the outcomes of cerebrovascular bypass surgery for Moyamoya disease, particularly in patients with hemorrhagic events. By addressing the complexities and challenges of treating Moyamoya disease, Aoki's work underscores the need for continued research and innovation in this field to improve patient care and outcomes.

# Chapter 10

## Neurosurgical Innovations and Technical Notes

### Ultrafine Microsurgical Techniques

Ultrafine microsurgical techniques are advanced surgical methods that use specialized instruments and microscopes to perform intricate procedures with extreme precision. These techniques are often used in delicate surgeries, such as nerve repair, blood vessel anastomosis, and organ transplantation. The use of high-powered microscopes allows surgeons to work on a very small scale, often using sutures and instruments that are finer than a human hair. This level of precision is crucial in minimizing tissue damage and ensuring optimal outcomes for patients. Ultrafine microsurgical techniques have revolutionized modern surgery, enabling surgeons to perform complex procedures with greater safety and effectiveness.

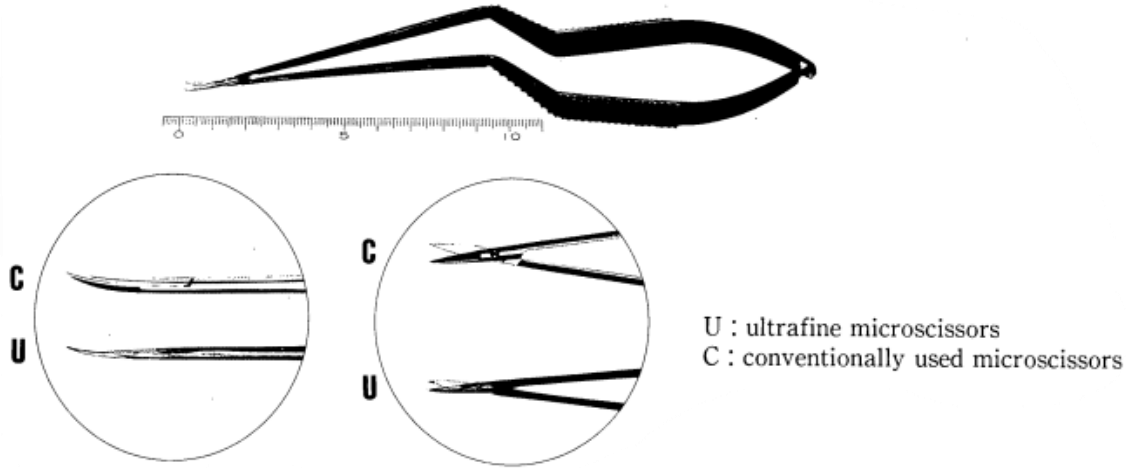
### Technical Note on Ultrafine Microneurosurgical Instruments

In the realm of neurosurgery, where precision is paramount, technological advancements have ushered in a new era of enhanced optical instruments. Notably, a cutting-edge operating microscope boasting magnification capabilities of up to 22 times and a brightness factor of  $16 \times 10^4$ , courtesy of Carl Zeiss Co., Ltd. in Germany, has emerged. This remarkable tool has not only heightened the clarity and visibility within the surgical field but has also brought to light a pressing need for the refinement of microsurgical techniques. As surgical procedures increasingly unfold under the scrutiny of such high magnification, the demand for microsurgical instruments capable of operating within these intensified conditions has surged.

However, the development of instruments fine-tuned to navigate these highly magnified terrains has lagged behind. Recognizing this gap, the authors, led by Nobuhiko Aoki, have embarked on a journey to craft a range of ultrafine microneurosurgical instruments. In this chapter, we delve into the utility and impact of these recently devised microsurgical instruments, illuminating their capacity to mitigate the morbidity associated with neurosurgical procedures.

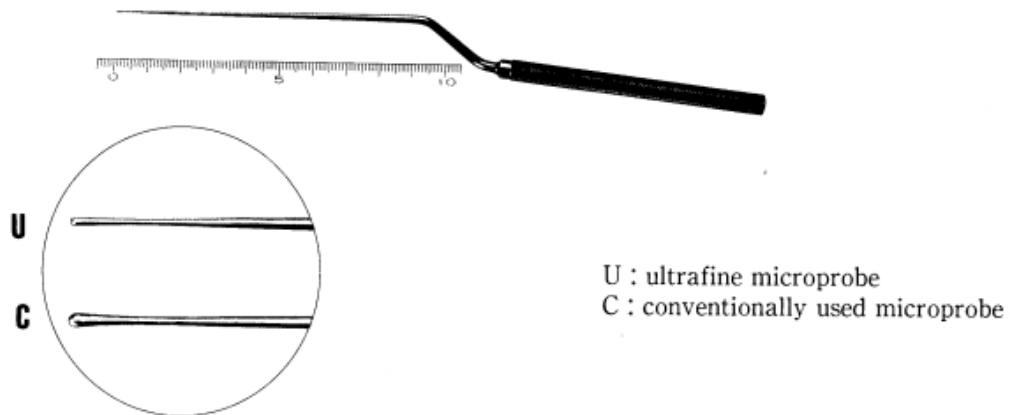
### Instruments for Fine Neurosurgery

**1. Microscissors:** These microscissors stand out for their incredibly sharp and thin tips, designed to be as precise as possible. They come in two variations: straight and slightly curved (see Figure 1).




*Fig.1 Microscissors*

**2. Dissecting Microprobes:** We've developed microprobes with blunt tips that are smaller than the ones typically used. They also come in two types: straight and slightly angled (see Figure 2).



*Fig.2 Dissecting microprobe*

**3. Tapered Retractors:** Our tapered retractors, originally conceptualized by Sugita et al., come in seven different sizes. They are coated in black and have varying widths ranging from 0.5mm to 6.0mm. The tips, particularly thin at 0.4mm thickness and 15mm in length, are ideal for delicate maneuvers (see Figure 3). All these microsurgical instruments are produced by Fujita Ika Corporation in Tokyo, Japan.



*Figure 3: Tapered Retractors. The size (in millimeters) shows the width of the tip of the tapered retractor. Pay attention to the thinner part of the tip, marked by an arrow.*

Since 1989, our team, led by Nobuhiko Aoki, has exclusively used these instruments in surgeries for cerebral aneurysms, arteriovenous malformations, and deep-seated brain tumors. Here's how we use them:

During surgery, the assistant neurosurgeon handles two types of tapered retractors, selecting the size suitable for the fissures or sulci being dissected. These retractors are intermittently used to mildly retract arachnoid membranes, the cerebral cortex, and vascular structures. Continuous retraction with a self-retaining apparatus is avoided, except in rare cases like the rupture of cerebral aneurysms.

The operating neurosurgeon identifies structures between the tapered retractors by suctioning various sizes of cotton patties to absorb cerebrospinal fluid and blood. With a maximally magnified view, the surgeon dissects these structures using microprobes and microscissors. Especially around the neck of an aneurysm, direct retraction of vascular structures using 0.5mm and 1.0mm tapered retractors facilitates precise dissection with microscissors.

## **Intracranial Lesion Surgery**

Microneurosurgery aims to minimize brain and vascular structure retraction during surgery. This is achieved by directly visualizing a narrow operative space under high magnification and excellent lighting. The ultrafine microsurgical instruments introduced here are specifically designed to access deep-seated intracranial lesions with minimal brain retraction, without damaging small blood vessels.

Recent advancements in neurosurgical techniques emphasize intermittent and gentle brain and vascular structure retraction, avoiding the use of self-retaining retractors unless absolutely necessary. To assist in this approach, retractors of various sizes suitable for specific operative fields are essential. Tapered retractors, originally developed by Sugita et al., are particularly valuable for delicate manipulation by the surgical assistant. Our tapered retractors, with widths of 0.5mm and 1.0mm, can also double as dissecting instruments due to their fine tips.

In our recent experience, these tapered retractors were especially beneficial in surgeries involving basilar artery aneurysms, where direct retraction of the artery's neck and main trunks was necessary. The use of bipolar coagulators during microsurgery has become less frequent since the introduction of our microprobes and microscissors. These instruments allow for precise dissection while sparing delicate vascular structures under highly magnified vision.

As operating microscopes continue to evolve, there is a growing demand for even finer microsurgical instruments in the future. Technological advancements in both instruments and microscopes will enable surgeons to access deep brain regions with minimal retraction, without compromising blood vessels.

## **Needle Brain Necropsy: A Novel Technique**

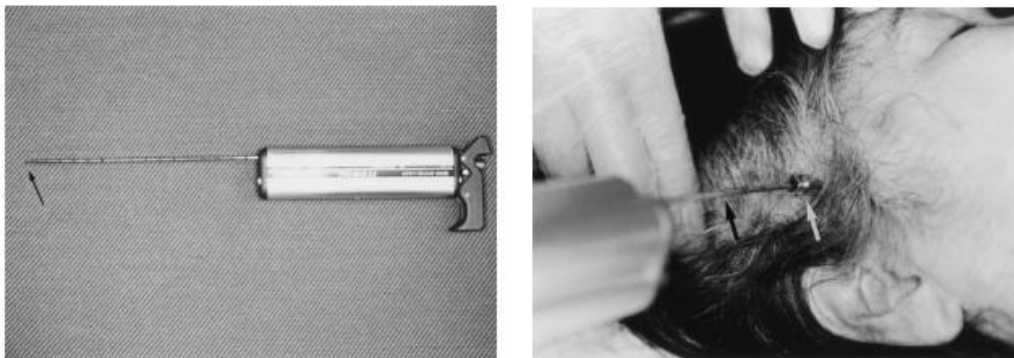
Needle Brain Necropsy is an innovative technique used for examining brain tissue post-mortem. Unlike traditional methods that involve extensive dissection, this approach utilizes a fine needle to extract small samples of brain tissue for analysis. The needle is carefully inserted into specific regions of the brain, allowing for precise sampling without causing significant damage. This technique is particularly useful in cases where preserving the integrity of the brain tissue is crucial, such as in research studies or forensic investigations. By minimizing tissue disruption, Needle Brain Necropsy enables researchers to obtain accurate data while maintaining the overall structure of the brain. This novel technique represents a significant advancement in post-mortem examination methods, offering a less invasive and more targeted approach to brain tissue analysis.

## **Technical Note on Needle Brain Necropsy via Percutaneous Craniostomy**

Confirming the presence of a brain tumor through histopathological analysis is crucial for clinical decision-making and cancer treatment. A straightforward method is explained for collecting

postmortem brain tissue samples with minimal scalp injury from a patient with an unconfirmed brain tumor. A 59-year-old woman initially suffered from a putaminal hemorrhage, later revealed by brain scans to be caused by a malignant glioma. Despite the tumor not being definitively diagnosed due to family refusal for biopsy or surgery, postmortem examination with nearly invisible scalp wounds was permitted. The needle necropsy technique involved creating a small hole in the skull using a twist drill needle at the bedside, then inserting a specialized needle along the path to the tumor's central area.

A kidney biopsy needle was then used to collect tissue samples from three different spots within the tumor. The histological analysis confirmed the diagnosis as glioblastoma. This simple technique allows for needle necropsy of brain pathology with minimal scalp trauma, even in cases where conventional necropsy is not permitted by the family. (See Figure 4 for illustration.)



*Figure 4 shows a biopsy needle used for taking samples in kidney diseases. An arrow points to the tip of the needle on the left image. On the right image, the kidney biopsy needle (marked with a black arrow) is being inserted through the outer needle (marked with a white arrow) of the subdural tapping needle.*

## **Conclusion**

In conclusion, the techniques described, particularly the Needle Brain Necropsy via Percutaneous Craniostomy, represent significant advancements in post-mortem examination methods, offering less invasive and more targeted approaches to brain tissue analysis. These methods, spearheaded by author Nobuhiko Aoki, are crucial for confirming brain tumors and guiding clinical decisions, especially in cases where conventional diagnostic procedures are not feasible. By enabling precise sampling of brain tissue with minimal scalp injury, these techniques offer hope for accurate diagnosis and improved understanding of intracranial pathology.

Furthermore, the utilization of specialized tools, such as the kidney biopsy needle, enhances the effectiveness of these procedures, making them accessible even in challenging situations where conventional necropsy is not permitted. Overall, these innovative techniques have the potential to

revolutionize post-mortem neuropathology and enhance patient care in the field of neurosurgery and oncology.

## **Publications as first author (1984-2024)**

### **1984**

1. Aoki N, Mizutani H: Does moyamoya disease cause subarachnoid hemorrhage ? Review of 54 cases with intracranial hemorrhage confirmed by computerized tomography. J Neurosurg 60 (2): 348-353, 1984
2. Aoki N: Subdural tapping and irrigation for the treatment of chronic subdural hematoma in adults. Neurosurgery 14 (5): 545-548,1984
3. Aoki N, Mizuguchi K: Chronic encapsulated intracerebellar hematoma in infancy. Case report. Neurosurgery 14 (5): 594-597,L984
4. Aoki N, Masuzawa H: Infantile acute subdural hematoma. Clinical analysis of 26 cases. J Neurosurg 61 (2): 273-280,1984
5. Aoki N: Moyamoya syndrome in twins. Neurosurgical forum. J Neurosurg 61 (3): 617, 1984
6. Aoki N: Intracranial changes with unilateral coronal synostosis. Surg Neurol 22(3): 249-252,1984
7. Aoki N: Interhemispheric subdural hematoma. Neurosurgical forum. J Neurosurg 61 (6): 1159, 1984

### **1985**

8. Aoki N: Acute toxic encephalopathy with symmetric low density areas in the thalami and the cerebellum. Child's Nerv Syst 1" (1): 62-65, 1985
9. Aoki N: Subdural hematoma in infants. Neurosurgical forum. J Neurosurg 62 (2): 316-317, 1"985
10. Aoki N: Moyamoya disease and subarachnoid hemorrhage. Letter to the editor. Surg Neurol 23 (2): 202-203, 1985
11. Aoki N: Cerebral hemorrhage. Letter to the editor. Surg Neurol 23 (2): 203,1985
12. Aoki N: Steroids and avascular necrosis of bone. Neurosurgical forum. J Neurosurg 62 (3): 459, 1985
13. Aoki N, Mizutani H: Communicating triventricular hydrocephalus and its treatment with a Lumboperitoneal shunt. Neurosurgery 16 (4): 557-561,1985
14. Aoki N, Mizutani H: Arteriovenous malformation in the territory of the occluded middle cerebral artery with intraoperative brain swelling. Case report. Neurosurgery 16 (5): 660-662, 1985
15. Aoki N: Hydrocephalus shunt efficacy. Correspondence. Neurosurgery 16 (6): 876, 1985

16. Aoki N, Mizutani H, Masuzawa H: Unilateral subdural-peritoneal shunting for bilateral chronic subdural hematomas in infancy. Report of three cases. *J Neurosurg* 63 (1): 134-137, 1985
17. Aoki N: Vascular decompression of the brain stem. *Neurosurgical forum. J Neurosurg* 63 (2): 310, 1985
18. Aoki N: Contrast enhancement of cerebellar infarction on computed tomography. *Surg Neurol* 24 (2): 141-150, 1985
19. Aoki N: Acute subdural hematoma in infancy. Correspondence. *Neurosurgery* 17 (3): 529-530, 1985
20. Aoki N: Contralateral gaze deviation after frontal lobe haemorrhage. Matter arising. *J Neurol Neurosurg Psychiatry* 48 (12): 1310, 1985
21. Aoki N: Benign intracranial hypertension. Letter to the editor. *Child's Nerv Syst* 1 (5): 243, 1985
22. Aoki N: Combined occipital transtentorial and infratentorial supracerebellar approach in the Concorde position for the treatment of an arteriovenous malformation in the upper vermis. Case report. *Neurosurgery* 17 (5): 815-817, 1985
23. Aoki N: Moyamoya disease. Correspondence. *Neurosurgery* 17 (6): 1015-1016, 1985
24. Aoki N: Low density lesions with mass effect on CT. Letter to the editor. *Acta Neurochir (Wien)* 78 (3-4): 182-183, 1985
25. Aoki N: CT appearance with Dandy-Walker variant and holoprosencephaly. Letter to the editor. *Child's Nerv Syst* 1 (5): 305, 1985

## **1986**

26. Aoki N, Mizuguchi K: Expanding intracerebellar hematoma. A possible clinicopathological entity. *Neurosurgery* 18 (1): 9a-96, 1986
27. Aoki N: Bilateral chronic subdural and communicating effusions in infancy. Letter to the editor. *Acta Neurochir (Wien)* 81 (1-2): 79, 1986
28. Aoki N: Hydrocephalus after subarachnoid hemorrhage. Letter to the editor. *Acta Neurochir (Wien)* 81 (1-2): 80-81, 1986
29. Aoki N: Steroid induced avascular necrosis of bone in neurosurgical patients. *Surg Neurol* 25 (2): 194-196, 1986
30. Aoki N: Reversible leucoencephalopathy caused by 5-Fluorouracil derivatives, presenting as akinetic mutism. *Surg Neurol* 25 (3): 279-282, 1986
31. Aoki N: Subarachnoid hemorrhage and AVM. Correspondence. *Neurosurgery* 18 (3): 387, 1986

32. Aoki N: Moyalnoya disease. Correspondence. :Neurosurgery 18(3): 387-388,1986
33. Aoki N:Aneurysln ofthe PICA. Correspondence. Neurosurgery 18(3): 388,1986
34. Aoki N,Nagao T: Resolution Of hemifacial spasm after posterior fossa exploration without vascular decolm.pression. Neurosurgery 18(4): 478-479,1986
35. Aoki N: A.trophic brain at high risk in neurosurgery. Report of a case Complicated by post-operative intraCerebral hemorrhage and tension pneurnocephalus Neurosurgery 18(4):475-477,1986
36. Aoki N,Masuzawa I]: Subdural hematoma in abused children Report of six cases fronl Japan.Neurosurgery 18(4):475-477,1986
37. Aoki N: Cerebellar arteriovenous Inalfornlationso Correspondence. Neurosurgery 18(4):516,1986
38. Aoki N:Brain damage fr011l boxing.Neurosurgical foruml.J Neurosurg 64(5): 829-830,1986
39. Aoki N: LarSen'S SyndrOIne with hydrocephalus. Surg Neuro1 25(6):587-590,1986 -
40. Aoki N: Hydrocephalus and hydranencephalyo Letter tO the editor. Surg Neuro1 26(6):600,1986
41. Aoki N: Air in acute epidural henlatolna. Report of two cases. J.Neurosurg 65(4):555-556,1986
42. Aoki N, Royofuku T,Komiya K:Cerebellar infarctiono Neuropediatrics 17(3): 124-128,1986
43. Aoki N: Treatment Of chrOnic subdural helnatO11la in adults. Letter to tle editor.Acta Neurochir(Wien)83(1-3): 75-76,1986
44. Aoki N: Cyst of the septum pellucidum presenting as hemiparesis. Case report. Chiid's Nerv Syst 2 (6): 326-328, 1986

## **1987**

- 45。 Aoki N:Brain dalnage from boxingo Neurosurgical forum. .J Neurosurg 66(1): 153-154,1987
46. Aoki N: :Percutaneous subdural tapping for the treatment of chronic subdural hematoma in adults.Neurological Research 9(1): 19-23,1987
- 47.Aoki N:Acute subdural hematolna of arterial origin in a patient with lumboperitoneal shunt。 Neurol Med Chir(Tokyo)27(1):60-62,1987
48. Aoki N:Caudate head helnorrhage caused by asymptomatic occlusion of middle cerebral artery.Surg Neuro1 27(2)1 173-176,1987

49. Aoki N: Incision of facial nerve branch at aneurysm surgery. Neurosurgical forum. J Neurosurg 66(3):482,1987
50. Aoki N: ]Lumboperitoneal shunt for the treatment of hydrocephalus in prenatally born infants, Acta Neurochir(Irien)84(3-4): 103-104,1987
51. Aoki Ni Communicating fourth ventricular hydrocephalus Case report. Neurosurgery 20(5):806-808,1987
52. Aoki N: Interhemispheric approach to carotid ophthalmic aneurysm clipping Case report. J Neurosurg 67(2):298-295,1987
53. Aoki N: Acute subdural hematoma in patients with intractable epilepsy. Neurology 31(7):651-653,1987
54. Aoki N: Cerebellar hematoma in childhood Letter to the editor. Child's Nerv Syst 3(1): 1,1987
55. Aoki N: Pneumocephalus after ventriculoperitoneal shunting. Correspondence, Neurosurgery 20(4):667-668,1987
56. Aoki N: Attenuation in epidural hematoma. Neurosurgical forum. J Neurosurg 66 (5): 789, 1987
57. Aoki N: Non tumoral aqueduct stenosis and normal pressure hydrocephalus in the elderly. Matters arising. J Neuro Neurosurg Psychiatry 50 (5): 648, 1987
58. Aoki N: Spontaneous intracerebral pneumocephalus. Correspondence. Neurosurgery 20 (6): 995, 1987
59. Aoki N: Infantile acute subdural hematoma. To the editor. Child's Nerv Syst 3 (4): 193,1987
60. Aoki N: Destructive hydrocephalus and porencephaly combined with the hydrocephalic process. To the editor. Child's Nerv Syst 3 (4): L94, 1987
61. Aoki N: Infantile acute subdural hematoma and its computed tomography features. To the editor. Child's Nerv Syst 3 (6): 326, 1987
- 1988**
62. Aoki N, Mizutani H: Acute subdural hematoma due to minor head trauma in patients with a lumboperitoneal shunt. Surg Neurol 29 (1): 22-26,1999
63. Aoki N: Sunken brain syndrome. Case report. Neurol Med Chir (Tokyo) 28 (6): 601-603, 1988
64. Aoki N: Acute subdural hematoma during tack-up suturing of the duramater. Neurol Med Chir (Tokyo) 28 (10): 994-995, 1988

65. Aoki N: Partially thrombosed aneurysm presenting as sudden onset of bitemporal hemianopia. *Neurosurgery* 22 (3): 564-566, 1988
66. Aoki N: Conversion of a lumboperitoneal shunt to a lumbocisternal shunt through femoral catheterization. Technical note. *Neurosurgery* 22 (2): 438-439, 1988
67. Aoki N: Brain damage due to head trauma in a patient with compensated hydrocephalus. *Neurol Med Chir (Tokyo)* 28 (6): 598-600, 1988
68. Aoki N: Subdural effusion in the acute stage of Kawasaki disease (Mucocutaneous lymph node syndrome). *Surg Neurol* 29 (3): 216-217, 1988
69. Aoki N: Rapid resolution of acute epidural hematoma. Report of two cases. *J Neurosurg* 68 (1): 149-151, 1988
70. Aoki N: Functioning ventricular shunting with extraventricular location of the catheter tip on computed tomography. *Child's Nerv Syst* 4(2): 105-107, 1988
71. Aoki N, Masuzawa H: Bilateral chronic subdural hematomas without communication between the hematoma cavities. Treatment with unilateral subdural-peritoneal shunt. *Neurosurgery* 22 (5): 911-913, 1988.
72. Aoki N: Acute subdural hematoma resulting from child abuse in two siblings. *J Pediatric Neurosciences* 3 (D): 99-103, 1988
73. Aoki N: Atlantoaxial dislocation presenting as sudden onset of quadriplegia in Down's syndrome. *Surg Neurol* 30 (2): 153-155, 1988
74. Aoki N: Abnormally enlarged fourth ventricle. Letter to the editor. *Surg Neurol* 29 (5): 414, 1988
75. Aoki N: Rebleeding from ruptured intracranial aneurysms. *Neurosurgical forum. J Neurosurg* 68 (6): 989-990, 1988
76. Aoki N: Resolution of intracranial hematoma. *Neurosurgical forum. J Neurosurg* 69 (1): 149-150, 1988
77. Aoki N: Symptomatic low ICP in shunted hydrocephalus. *Neurosurgical forum. J Neurosurg* 69 (B): 476-477, 1988
78. Aoki N: Postoperative tension pneumocephalus. *Neurosurgical forum. J Neurosurg* 69 (4): 641, 1988
79. Aoki N: Managing proximal shunt obstruction. *Neurosurgical forum. J Neurosurg* 69 (5): 80b-806, 1988
80. Aoki N: Acute subdural hematoma after ventriculoperitoneal shunting. Letter to the editor. *Surg Neurol* 20 (4): 327- 328, 1988

## 1989

81. Aoki N: Intraventricular cryptococcal granulomas. Case report. *Neurol Med Chir (Tokyo)* 29 (3): 251-254, 1989
82. Aoki N, Sakai T: Cerebral sinus thrombosis in patients with severe iron deficiency anemia due to myoma uteri. *Acta Neurochir (wien) gT (B-4)*: 131-134, 1989
83. Aoki N: Subcutaneous absorption of cerebrospinal fluid in an infant with hydrocephalus. *J pediatric Neurosciences* 4 (4): 291-295, 1989
84. Aoki N: Lumboperitoneal shunt for the treatment of postoperative persistent collection of subcutaneous cerebrospinal fluid (pseudomeningocele). *Acta Neurochir (wien)* 98 (1-2): 32-34, 1989
85. Aoki N: Modified skull clamp procedure. Correspondence. *Neurosurgery* 24(2): 299, 1989
86. Aoki N: von Recklinghausen's neurofibromatosis and aqueduct stenosis. Correspondence. *Neurosurgery* 25(2): 318-319, 1989
87. Aoki N: Views on microvascular compression. *Neurosurgical forum. J Neurosurg* 71 (3): 462, 1989
- BB. Aoki N: LP shunting in cases of Chiari malformation. *Neurosurgical forum. J Neurosurg* 71 (6): 953, 1989
89. Aoki N, Sakai T: Modified application of three-point skull clamp for infants. *Neurosurgery* 25 (4): 660-662, 1989

## 1990

90. Aoki N: "Occult" hydrocephalus in children. Letter to the editor. *Child's Nerv Syst* 6 (1): L-2, 1990
91. Aoki N, Sakai T, Imezawa Y: Slit ventricle syndrome after cyst-peritoneal shunting for the treatment of intracranial arachnoid cyst. *Child's Nerv Syst* 6 (1): 41-43, 1990
92. Aoki N, Sakai T: Intraoperative subdural hematoma in a patient with arachnoid cyst in the middle cranial fossa. *Child's Nerv Syst* 6 (1): 44-46, 1990
93. Aoki N, Sakai T, Oikawa A, Tsutsumi K: Significance of preserving bridging veins in an interhemispheric approach. Letter to the editor. *Surg Neurol* 33 (2): 159-160, 1990
94. Aoki N: Injection of tissue plasminogen activator to prevent delayed vasospasm. Correspondence. *Neurosurgery* 26 (3): 549-550, 1990 .
95. Aoki N, Tsutsumi K: Symptomatic subacute subdural haematoma following spontaneous acute subdural haematoma. *Acta Neurochir (Wien)* 102 (3): 149-151, 1990

96. Aoki N: Acute subdural haematoma with rapid resolution. *Acta Neurochir (Wien)* 103 (1): 76-78, 1990
97. Aoki N, sakai T: Avulsion of choroid plexus during revision of ventricular shunting; its high incidence and predictive value of computed tomography. *Surg Neurol* 83 (4): 256-260, 1990
98. Aoki N: use for dural elevator. *Neurosurgical forum. J Neurosurg* T2(5): 834, 1990
99. Aoki N: Lumboperitoneal shunting: crinical applications, complications, and a comparison with ventriculoperitoneal shunting. *Neurosurgery* 26 (6): 993-1004, 1990
100. Aoki N: chronic subdural hematoma in infancy: crinical analysis of 30 cases in the era of computed tomography. *J Neurosurg* S 72 (2):201-208, 1990
101. Aoki N: Rapid growth of intraspinal lipoma demonstrated by magnetic resonance imaging. *Surg Neurol* 34 (2):107-110, 1990
102. Aoki N, sakai T: Rebreeding from intracranial dissecting aneurysm in the vertebral artery. *Stroke* 21 (1):162-168, 1990
103. Aoki N: Epidural haematoma in the newborn infants: Therapeutic consequences from the correlation between haematoma content and computed tomography features. A review. *Acta Neurochir* 106(1): 65-67, 1990
104. Aoki N: Acute subdural hematoma in infants. *Neurosurgical forum. J Neurosurg* 73 (4):645, 1990

### **1991**

105. Aoki N, sakai T, oikawa A: Intracranial arteriovenous fistula manifesting as progressive neurological deterioration in an infant: case report. *Neurosurgery* 28 (4):619-623, 1991
106. Aoki N: Syringomyelia secondary to congenital intraspinal lipoma. *Surg Neurol* 34 (5): 360-365, 1991
107. Aoki N: Does the siphon effect of cerebrospinal fluid shunting develop in vivo? Report of a case casting doubt on the presence of this phenomenon. *Neurol Res* 13 (2): 128-130, 1991
108. Aoki N: Treatment for intraventricular hemorrhage. *Neurosurgical forum. J Neurosurg* TS (3):AgL-agb, 1991
109. Aoki N, Sakai T, Oikawa A: Acute subdural haematoma successfully treated by percutaneous subdural tapping in an elderly. *Acta Neurochir (Wien)* 111 (3): 132-134, 1991
110. Aoki N: Do intracranial arteriovenous malformation cause subarachnoid haemorrhage? Review of computed tomography features of ruptured arteriovenous malformation in the acute stage. *Acta Neurochir (Wien)* 112 (3):92-95, 1991

111. Aoki N: Rapid bedside technique for percutaneous ventricular drainage in patients with severe subarachnoid hemorrhage. Technical note. *Acta Neurochir (Wien)* 113 (3): 184-18b, 1991

## 1992

112. Aoki N, Sakai R, Kaneko M: Traumatic aneurysm of the middle meningeal artery presenting as delayed onset of acute subdural hematoma. *Surg Neurol* 37 (1): 59-62, 1992

113. Aoki N: The copitoneal shunting. *Neurosurgical forum. J Neurosurg* 76 (1): 773-174, 1992

114. Aoki N: Posterior circulation dissections. *Neurosurgical forum. N Neurosurg* 76 (3): 562-563, 1992

115. Aoki N: Infantile acute encephalopathy with symmetrical hypodensities in the thalami and the putamen on computed tomography. *Neurol Res* 14:252-4, 1992

116. Aoki N: A new therapeutic method for chronic subdural hematoma in adults: Replacement of the hematoma with oxygen via percutaneous subdural tapping. *Surg Neurol* 38:253-256, 1992

## 1993

117. Aoki N, Sakai: Computed tomography features immediately after replacement of hematoma with oxygen through percutaneous subdural tapping for the treatment of chronic subdural hematoma in adults. *Acta Neurochir (Wien)* 120:44-46, 1993

118. Aoki N, Sakai L, Oikawa A: Vertebral artery aneurysm at the level of cervico medullary junction. Case report. *Neurol Med Chir* 33: 100-102, 1993

119. Aoki N, Sakai I, Oikawa A, Shiokawa Y: Ultrafine microsurgical technical note. *Jpn J Neurosurg (Tokyo)* 2:165-167, 1993

120. Aoki N: Subdural-peritoneal shunt. One-piece design with a large flushing device. *Childs Nerv Syst* 9:176-178, 1993

121. Aoki N: Cerebrovascular bypass surgery for the treatment of Moyamoya disease. Unsatisfactory outcome in patients presenting with intracranial hemorrhage. *Surg Neurol* 40:372-377, 1993

## 1994

122. Aoki N: Evolution of chronic subdural hematoma after burr-hole exploration for subdural hematoma. Case report. *Neurol Med Chir (Tokyo)* 36:385... 387, 1994

123. Aoki N: Extracerebral fluid collection in infancy. Role of magnetic resonance imaging in differentiation between subdural effusion and subarachnoid space enlargement. *J Neurosurg* 83:20-23, 1994

124. Aoki N: Accidental Head Trauma and Retinal Hemorrhage. *Neurosurgery* 14 :77 L, 1994 (Correspondence)

## 1995

125. Aoki N: "Head-shaking syndrome" neurological deterioration during continuous head-shaking as an adjunct to cisternal irrigation for clot removal in patients with acute subarachnoid haemorrhage. *Acta Neurochir(Wien)*112-125' 1995

126. Aoki N, Oikawa A, Sakai T: Spontaneous regeneration of the foramen Magnum after decompressive suboccipital craniectomy in Chiari Malformation. Case report *Neurosurgery* 37:340-342, 1995

## 1996

127. Aoki N, Oikawa A, Sakai T: Symptomatic subacute subdural hematoma associated with cerebral hemispheric swelling and ischemia. *Neurol Res* 18:145... 149' 1996

128. Aoki N, Oikawa A, Sakai T: Percutaneous subdural tapping for the treatment of chronic subdural hematoma associated with coagulopathy due to advanced cancer. Case report. *Jpn J Neurosurg* 5:313-316' 1996

## 1997

129. Aoki N, Oikawa A, Sakai T: Isolated ophthalmological Manifestations due to malfunction of a lumboperitoneal shunt. Shortening of the spinal catheter in three pediatric patients. *Childs Nerv Syst* 13:264-267' 1997

130. Aoki N' Sakai T' Oikawa A' Takizawa H Shishido T : Infected subdural effusion associated with resolving subdural hematoma case report *Neurol Med Chir(Tokyo)*637-639' 1997

131. Aoki N, Sakai T, Oikawa A, Takizawa T: Giant unruptured aneurysm of the vertebral artery presenting with rapidly progressing bulbar myelopathy. Case report. *Neurol Med Chir(Tokyo)*37:907-910' 1987

132. Aoki N, Sakai T, Oikawa A: Serial neuroimaging studies in Sotos syndrome (cerebral gigantism syndrome) *Neurol Res* 29:154-159, 1997

## 1998

133. Aoki N, Sakai T, Oikawa A: Spontaneous intracranial hypotension With subdural hematoma. Diagnostic usefulness of percutaneous subdural tapping and magnetic resonance imaging. *Acta Neurochir (Wien)*140:47-50' 1998

134. Aoki N, Sakai T, Oikawa A: Postoperative inflammatory reaction developing focal but severe brain edema. Possible complication of topical application of biobond-soaked oxycellulose *Acta Neurol Scand* 98:288-291' 1998

## 1999.

135. Aoki N, Sakai T, Oikawa A, Takizawa M, Koike M: Dissection of the middle cerebral artery caused by invasion of malignant glioma presenting as acute onset of hemiplegia. *Acta Neurochir (Wien)* 141:1005-1008, 1999

136. Aoki N, Oikawa A: Resolution of carotid artery stenosis after medical treatment. Case report. *Surgery for cerebral stroke* 27:489-492, 1999

## 2001

137. Aoki N, Ogura M, Oikawa A: Needle brain necropsy through percutaneous craniostomy. Technical note *Acta Neurochir (Wien)* 143, 2001

## 2020

138. Aoki N: Infantile Acute Subdural Hematoma with Retinal Hemorrhage Caused by Minor Occipital Impact Witnessed by an ICU Nurse: A Case Report. *Pediatr Neurol Neurosci* 4(1):47-50, 2020

139. Aoki N: "Infantile" Acute Subdural Hematoma: A Clinical Entity Different from Abusive Head Trauma. *J Pediatr Neurol Neurosci* 4(1):151-53, 2020

## 2023

140. Aoki N: Clinical and neuroimaging characteristics in mild-type infantile acute subdural hematoma. Report of four cases. 2023 doi:10.21203/rs.3.rs-2733567/v1

## 2024

141. Aoki N: Infantile acute subdural hematomatohydroneuric cyst: A clinical and neuroimaging analysis of 18 cases. *American Journal of Pediatrics* (Volume 10, Issue 1, March 2024) 26-33 DOI 10.11648/j.ajp.20241001.15